JVIN | Journal of Vascular and Interventional Neurology

OFFICIAL JOURNAL OF ZEENAT QURESHI STROKE INSTITUTE

Endovascular Rescue of Recurrent Airway-Threatening Hemorrhagic Thyroid Cyst

Easton Mickelson[1], BS, Austin Reed[1], BS, Aaron Higginbotham[1,*], BS, Domenico Napoletano[1], BS, Martin G. McCandless[2], MD, Jeremy Peterson[2], MD, Koji Ebersole[2], MD

[1] University of Kansas School of Medicine, Kansas City, Kansas, USA

[2] Department of Neurosurgery, University of Kansas Medical Center, Kansas City, Kansas, USA

Abstract

Introduction— Spontaneous thyroid hemorrhage is a rare but potentially life-threatening condition that can present with acute neck swelling and rapid progression to airway compromise. Management has traditionally involved surgery when significant mass effect is present.

Methods— We report a case of a 45-year-old man presenting with rapidly progressive anterior neck swelling, dysphagia, and voice changes. Clinical evaluation, imaging, endoscopic assessment, and angiographic findings were reviewed.

Results— Computed tomography demonstrated a 10.8 cm left thyroid mass with significant tracheal deviation. Flexible laryngoscopy revealed marked pharyngeal compression and edema. Given concern for airway compromise, the patient underwent emergent intubation and needle aspiration, yielding sanguineous fluid with transient improvement. Rapid reaccumulation prompted angiography, identifying active extravasation from distal branches of the left superior thyroid artery. This was treated with n-butyl cyanoacrylate (NBCA) embolization, achieving complete occlusion and clinical stabilization, and the patient was extubated without complication. Embolization served as a temporizing measure rather than definitive treatment: the patient subsequently underwent elective left hemithyroidectomy, which proceeded without complication and revealed no malignancy on pathology.

Conclusion— This case demonstrates the feasibility of endovascular embolization as a minimally invasive means of achieving hemorrhage control and temporary stabilization in airway-threatening thyroid hemorrhage, converting an emergent, high-risk surgical scenario into a delayed, elective procedure. Further cases are needed to characterize the broader role of this approach.

BACKGROUND

Spontaneous thyroid hemorrhage can present as acute neck swelling with the potential for rapid progression to airway compromise.[1,2] Rapidly expanding hematoma can produce critical airway narrowing requiring emergent intubation or surgical airway.[1,2] Most cases are self-limiting and managed conservatively. In a retrospective series of 59 patients presenting to a single emergency department over 10 years, acute neck pain, dyspnea, and dysphagia were the predominant complaints, and most cases followed a benign clinical course.[3] However, some patients develop substantial hematoma expansion resulting in tracheal deviation and compression requiring emergent intervention.[1,3]

Stable hemorrhage can be managed conservatively with observation and serial imaging.[2-4] Ultrasound-guided aspiration can decompress hemorrhagic cysts, though recurrence is common.[3] Progressive expansion or impending airway compromise warrants CT angiography to assess for active extravasation and tracheal compression.[2] Surgical drainage or hemithyroidectomy has been the standard approach for hemorrhage control in unstable patients,[2] while catheter-directed embolization has been reported in a small number of cases, though its role as a bridge to elective surgery has not been well characterized.[5,6]

We report a case of rapidly expanding hemorrhagic thyroid cyst causing severe airway compression and tracheal deviation in which initial aspiration produced transient decompression. Subsequent angiogram demonstrated active extravasation from distal branches of the superior thyroid artery, successfully stabilized with NBCA embolization and followed by elective hemithyroidectomy under nonemergent conditions.

Vol.16, No. 1, pp. 108-111, Published September, 2026.

All Rights Reserved by JVIN. Unauthorized reproduction of this article is prohibited.

*Corresponding Author: Aaron Higginbotham, Fourth-Year Medical Student, E-mail: Ahigginbotham@kumc.edu, ORCID: 0009-0002-1455-2327.

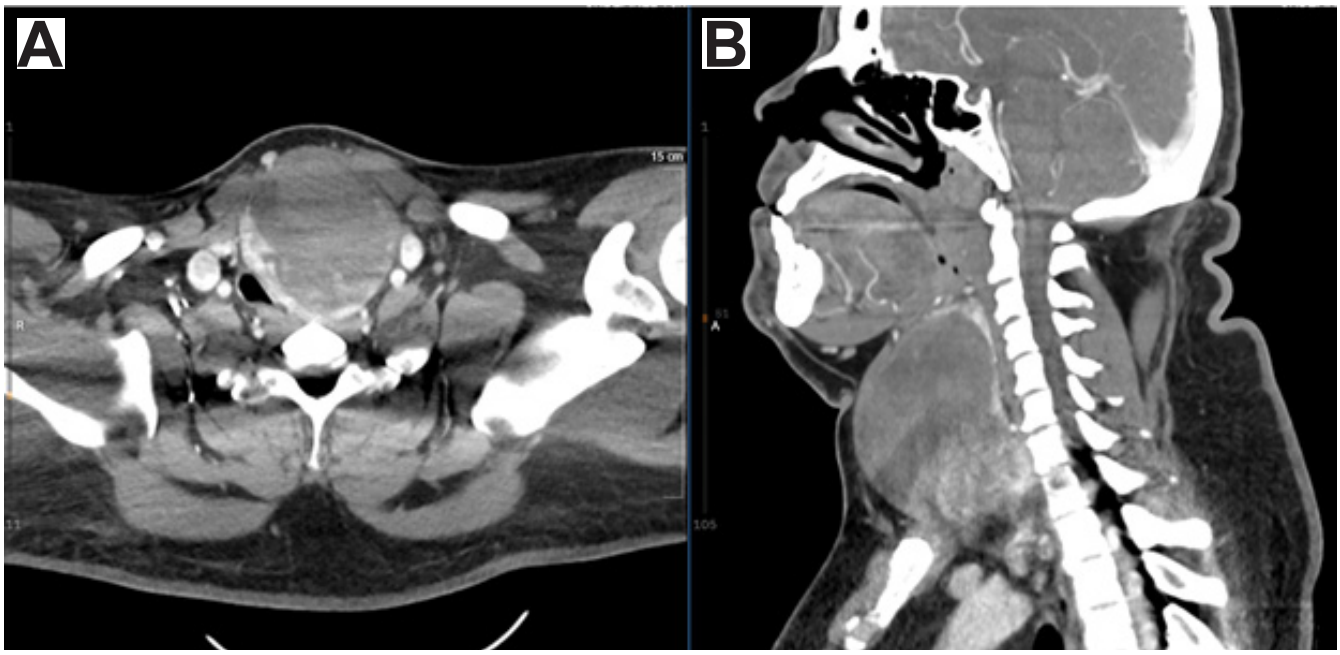

FIGURE 1: CT of the head and neck with contrast demonstrating a large thyroid mass compressing and displacing the trachea and esophagus on axial (left) and sagittal (right) slices.

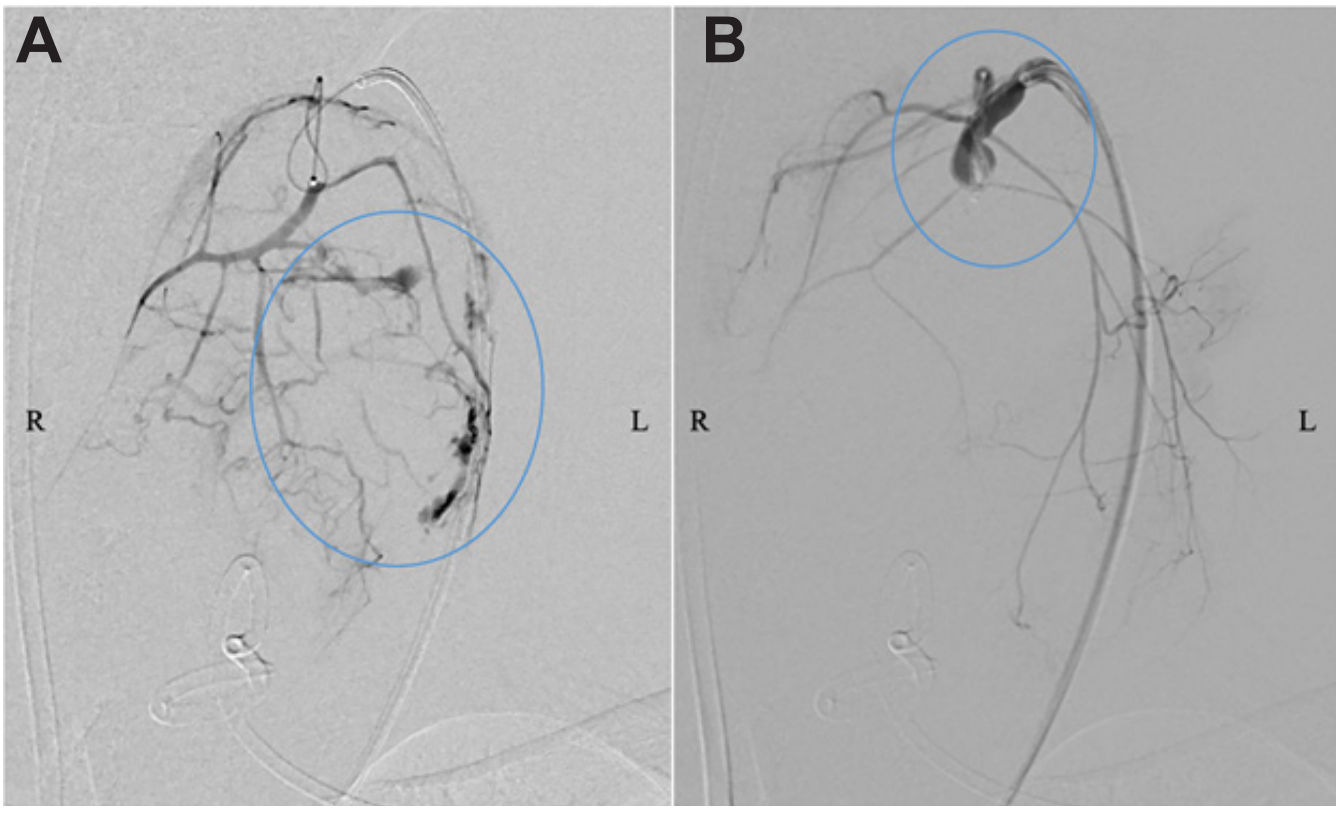

FIGURE 2: Anteroposterior (AP) angiogram of the left superior thyroid artery demonstrating a hemorrhage at the site of the thyroid mass (left). Post-embolization AP angiogram demonstrating occlusion of the parent vessel contributing to hemorrhage (right).

CASE PRESENTATION

A 45-year-old man presented with acute, rapidly progressive anterior neck enlargement, pain, dysphagia, and voice changes beginning one day prior. The patient reported a several-year history of recurrent, abrupt-onset, self-resolving left-sided anterior neck swelling, with more than one year without symptoms prior to this presentation. During a similar but milder episode in 2023, an ENT-directed ultrasound reportedly identified no abnormality; CT and biopsy were discussed but deferred after the swelling regressed, and a standing order for CT on recurrence was placed. No prior tissue sampling had been performed. Notably, the current episode extended across the midline to the contralateral neck, which the patient described as distinct from prior flares.

Initial CT of the neck at an outside hospital revealed a large left thyroid mass (7.9 x 6.6 x 10.8 cm) with rightward displacement of the trachea and esophagus (Figure 1). He was discharged with outpatient follow-up but returned the same day with worsening swelling, pain, and airway symptoms.

He was afebrile and hemodynamically stable but noted difficulty with deep inspiration due to pain, hoarseness, and dysphagia. Flexible laryngoscopy demonstrated substantial mass effect on the posterior pharynx with diffuse edema and obscured laryngeal structures. Laboratory studies were notable for leukocytosis (WBC 15.7 x 10^9/L), with otherwise normal thyroid function. He received periprocedural intravenous dexamethasone for airway edema.

Given rapid progression and airway compromise, he was taken emergently to the operating room, the airway secured via endotracheal intubation, and needle aspiration of the cyst yielded 15 mL of thick sanguineous fluid; the larynx returned to midline. Emergent hemithyroidectomy was considered but deemed high risk given the mass's size, rapid expansion, and distorted anatomy, so temporizing interventional therapy was pursued with a plan for delayed definitive surgery.

Ultrasound on hospital day 2 showed a persistent 10 cm hematoma replacing the left thyroid lobe despite aspiration the preceding day, raising concern for persistent arterial inflow. No CT angiogram was obtained. The patient was taken to the angiography suite where ultrasound-guided fine-needle aspiration was performed and a drain was placed, followed by diagnostic angiography via femoral access, revealing multifocal active contrast extravasation from distal branches of the left superior thyroid artery (Figure 2, left). These branches were embolized with n-butyl cyanoacrylate (NBCA), achieving complete occlusion with no residual contrast extravasation on final angiography (Figure 2, right). Mass effect resolved and expansion was halted; the patient was extubated on hospital day 4 and discharged on day 7.

He remained stable until definitive left hemithyroidectomy 55 days after initial presentation, which proceeded without complication despite substantial fibrosis and desmoplastic changes. The recurrent laryngeal nerve and parathyroid glands were preserved; no malignancy was identified. Postoperatively, the patient had stable voice, tolerated oral intake, and was discharged on postoperative day 1 without complications, with drain removal on postoperative day 3.

DISCUSSION

Spontaneous thyroid hemorrhage is a rare cause of acute neck swelling that can progress to life-threatening airway compromise. Because the thyroid gland is enclosed within the pretracheal fascia, hemorrhage in this confined space can produce compressive effects disproportionate to hematoma volume.[1-3] Here, rapid enlargement, tracheal displacement, pharyngeal edema, and obscured laryngeal landmarks on flexible laryngoscopy necessitated emergent intervention.[1,2]

Because emergent surgery was considered treacherous and initial aspiration insufficient, a temporizing interventional strategy was pursued. NBCA was selected because, as a liquid embolic that polymerizes rapidly on contact with blood, it can penetrate small, tortuous distal branches inaccessible to coils and provides more durable occlusion than particulate agents, which carry higher rebleeding risk.[7-9]

Management of airway-threatening thyroid hemorrhage has centered on surgical drainage or hemithyroidectomy.[3] Here, transient improvement after aspiration followed by sonographic reaccumulation suggested persistent arterial inflow rather than a simple hemorrhagic cyst, prompting angiography that identified extravasation from the left superior thyroid artery, consistent with prior reports of spontaneous superior thyroid artery rupture as a rare etiology of cervical hemorrhage.[10]

This case supports early catheter angiography when airway-threatening thyroid hemorrhage reaccumulates after decompression, as it may convert diagnostic uncertainty into targeted therapy. Embolization served not as definitive treatment but as a temporizing measure allowing surgery to be delayed until the patient was stable; elective hemithyroidectomy was performed nearly eight weeks later without complication. Thyroid arterial embolization is also feasible and effective for benign thyroid nodules.[11,12]

Limitations include the single case nature of this report and the risks of embolization, including nontarget embolization and tissue necrosis.[13] Embolization is not a replacement for surgery but rather an adjunct enabling extubation and discharge, allowing definitive surgery under controlled conditions.

CONCLUSIONS

Hemorrhagic thyroid cysts are a recognized cause of acute neck swelling, typically managed with aspiration and/or surgical resection. Reports of endovascular management remain rare. This case demonstrates targeted arterial embolization as a temporizing strategy that stabilized the patient and bridged him to successful elective hemithyroidectomy. When emergent surgery is high-risk, catheter-directed embolization may be a valuable addition to the management algorithm for airway-threatening thyroid hemorrhage, converting an emergent scenario into a controlled, staged approach.

REFERENCES

1. Best CAE, Dhaliwal S, Tam S, et al. Spontaneous intrathyroidal hematoma causing airway obstruction: A case report. Medicine (Baltimore) 2016;95(35):e3209. doi: 10.1097/MD.0000000000003209.
2. Tsilchorozidou T, Vagropoulos I, Karagianidou C, et al. Huge intrathyroidal hematoma causing airway obstruction: a multidisciplinary challenge. Thyroid 2006;16(8):795–9. doi: 10.1089/thy.2006.16.795.
3. Covino M, Princi P, De Luca G, et al. Spontaneous thyroid nodule hemorrhage in the emergency department. Endocr Pract 2020;26(2):192–6. doi: 10.4158/EP-2019-0326.
4. Terry M, Araujo A, Trott S, et al. Traumatic Intrathyroidal Hematoma: Case Report and Review of Literature. Head Neck 2026;48(1):E10–3. doi: 10.1002/hed.28248.
5. Coskun ZO, Yavaşi Ö, Durakoglugil T, et al. Acute airway compromise due to ruptured inferior thyroid artery aneurysm. Am J Emerg Med 2015;33(8):1115.e1-3. doi: 10.1016/j.ajem.2015.01.049.
6. Yang H, Zhao S, Zhang Z, et al. The associated factors for spontaneous intranodular hemorrhage of partially cystic thyroid nodules. Medicine (Baltimore) 2020;99(51):e23846. doi: 10.1097/MD.0000000000023846.
7. Kim HC, Miyayama S, Choi JW, et al. Embolization with N-Butyl Cyanoacrylate: Properties, Techniques, Applications, and Pitfalls. Radiographics, 46(5), Article e250122. doi:.10.1148/rg.250122.
8. Yonemitsu T, Kawai N, Sato M, et al. Evaluation of transcatheter arterial embolization with gelatin sponge particles, microcoils, and n-butyl cyanoacrylate for acute arterial bleeding in a coagulopathic condition. J Vasc Interv Radiol 2009;20(9):1176–87. doi: 10.1016/j.jvir.2009.06.005.
9. Kubo T, Yamana H, Aso S, et al. Association between embolic agent choice and complications after transcatheter arterial embolization for colonic diverticular bleeding. Eur Radiol 2026;36(5):3960–8. doi: 10.1007/s00330-025-12210-y.
10. Stenner M, Helmstaedter V, Spuentrup E, et al. Cervical hemorrhage due to spontaneous rupture of the superior thyroid artery: Case report and review of the literature. Head Neck 2010;32(9):1277–81. doi: 10.1002/hed.21213.
11. Yilmaz S, Habibi HA, Yildiz A, Altunbas H. Thyroid Embolization for Nonsurgical Treatment of Nodular Goiter: A Single-Center Experience in 56 Consecutive Patients. J Vasc Interv Radiol 2021;32(10):1449–56. doi: 10.1016/j.jvir.2021.06.025.
12. Cheng KL, Liang KW, Lee HL, et al. Thyroid artery embolization of large solitary symptomatic benign thyroid nodules through transradial approach. Quant Imaging Med Surg 2023;13(8):5355–61. doi: 10.21037/qims-22-1385.
13. Coerts HI, D'Mello B, Verburg FA, et al. Thyroid Arterial Embolization for the Management of Benign and Malignant Thyroid Disease: A Systematic Review. Endocr Pract 2026;32(1):67–76. doi: 10.1016/j.eprac.2025.07.024.