JVIN | Journal of Vascular and Interventional Neurology

OFFICIAL JOURNAL OF ZEENAT QURESHI STROKE INSTITUTE

# The Thyroid–Cerebrovascular Axis: Insights from Reported Cases of Concurrent Moyamoya and Graves' Disease

**Enes Demir[1], MD, Dorsa Farahnak[2], MD, Ammar Saloum[3], BS, Christine Chau[3], BS, Taylor Vadset[4], BS, Brandon Lucke-Wold[5], MD, PhD, Michael Karsy[6,]*, MD, PHD**

*[1] Department of Pathology, University of Michigan, Ann Arbor, Michigan, USA*

*[2] University of Turin, Italy*

*[3] Michigan State University College of Human Medicine, Lansing, MI, USA*

*[4] Albert Einstein College of Medicine, Bronx, NY, USA*

*[5] Department of Neurosurgery, University of Arizona, Tucson, Arizona, USA*

*[6] Department of Neurosurgery, University of Michigan, Ann Arbor, MI, USA*

## Abstract

**Background—** Moyamoya disease (MMD) is a progressive steno-occlusive cerebrovascular disorder characterized by impaired cerebral perfusion and fragile collateral formation. Graves' disease (GD), an autoimmune hyperthyroid condition, exerts systemic metabolic, vascular, and immunologic effects. Increasing clinical reports describe the coexistence of MMD and GD, suggesting a shared pathophysiological interface linking endocrine dysfunction and cerebrovascular instability. We aimed to synthesize reported cases to define clinical patterns, mechanistic links, and management implications.

**Methods—** We conducted a structured narrative review of PubMed through January 2026 using the terms "Moyamoya" and "Graves' disease." Studies reporting original patient data with concurrent MMD and GD were included following screening and eligibility assessment based on predefined criteria. Non-English articles and reviews without case-level data were excluded. Data were analyzed qualitatively to identify recurring clinical, temporal, and therapeutic patterns.

**Results—** Across reported cases, a consistent clinical pattern emerges in which ischemic cerebrovascular events frequently occur during periods of active thyrotoxicosis. Hyperthyroid states exacerbate perfusion vulnerability through increased metabolic demand, sympathetic activation, and hemodynamic instability in the setting of impaired cerebrovascular reserve. Autoimmune mechanisms, including thyroid autoantibody-mediated endothelial dysfunction, may further contribute to vascular injury and disease progression. Recurrent ischemic events are most commonly associated with uncontrolled or relapsed hyperthyroidism, whereas restoration of euthyroid status is linked to clinical stabilization. Surgical revascularization, typically deferred until endocrine control is achieved, is associated with favorable neurological outcomes.

**Conclusions—** The coexistence of MMD and GD represents a reproducible clinicopathologic entity in which thyrotoxicosis acts as a modifiable trigger of ischemic events. A two-hit model—baseline autoimmune-mediated vascular susceptibility with superimposed thyrotoxicosis-induced metabolic and hemodynamic stress—best explains observed patterns. Prioritizing rapid achievement and maintenance of euthyroidism, alongside coordinated neurovascular management, is essential to reduce neurologic risks and optimize surgical outcomes.

## 1. INTRODUCTION

Moyamoya disease (MMD) is a chronic, progressive cerebrovascular arteriopathy characterized by stenosis or occlusion of the terminal internal carotid arteries and their proximal branches.[18] This results in the development of fragile basal collateral networks and the classic "puff of smoke" appearance on angiography. Clinically, MMD includes ischemic and hemorrhagic phenotypes and may present with transient ischemic attacks, ischemic stroke, intracranial hemorrhage, seizures, or chronic headache. Diagnosis is imaging-based (MRA/CTA, with digital subtraction angiography as the reference standard) and is often supplemented by perfusion or hemodynamic studies when operative planning is being considered. While medical therapy may support symptom control and secondary prevention, definitive risk reduction typically relies on

Vol.16, No. 1, pp. 44-62, Published June, 2026.

All Rights Reserved by JVIN. Unauthorized reproduction of this article is prohibited.

*Corresponding Author: Michael Karsy. Email: mkarsy@med.umich.edu. Tel: +1-734-936-7010

surgical revascularization (direct, indirect, or combined bypass).

Graves disease (GD) is the most common cause of autoimmune hyperthyroidism and is driven by thyroid-stimulating immunoglobulins activating the TSH receptor, resulting in excessive thyroid hormone production.[15] In addition to systemic manifestations such as palpitations, weight loss, tremor, and heat intolerance, GD reflects broader immune dysregulation and can involve extrathyroidal features such as ophthalmopathy. Thyrotoxicosis also has significant cardiovascular and vascular effects, including increased heart rate and cardiac output, altered vascular tone, and increased metabolic demand. In parallel, inflammatory and endothelial changes are proposed to contribute to vascular instability during active disease.

Over the past two decades, increasing attention has focused on the co-occurrence of MMD and GD, raising the possibility of a biologically meaningful association rather than a coincidental overlap. This association was initially described in isolated case reports and small case series and later reinforced by larger clinical datasets. Early descriptions emphasized temporal clustering of neurologic events with hyperthyroid states,[45,47] while later series expanded the demographic and geographic spectrum.[33,34,40,46] More recently, retrospective population-level analyses have suggested that this concurrence, although uncommon, is clinically meaningful and warrants systematic attention in both endocrine and neurovascular settings.[14]

The simultaneous or near-simultaneous presentation is clinically important for two practical reasons. First, thyrotoxicosis may lower the threshold for cerebral ischemia in patients with compromised cerebrovascular reserve, particularly during physiologic stress (tachyarrhythmia, dehydration, fever, perioperative instability), as repeatedly reported in case series.[16,46] Second, the autoimmune nature of GD raises the possibility of a shared pathogenic mechanism, in which the immune-mediated endothelial dysfunction, inflammatory signaling, and shared susceptibility factors contribute to MMD pathogenesis or progression in a subset of patients.[36,40]

This review synthesizes clinical patterns of concurrent MMD and GD, with emphasis on the temporal relationship between thyroid activity and neurologic events, recurring demographic and presentation features, and management strategies that prioritize endocrine stabilization while addressing cerebrovascular risk. In addition, we examine the potential mechanistic interplay linking these conditions.

The distinction between moyamoya disease and moyamoya syndrome remains a subject of ongoing debate, particularly in cases associated with systemic conditions such as Graves' disease. In this review, we use the term moyamoya disease for consistency with the cited literature, while recognizing that some cases may represent secondary moyamoya vasculopathy.

We propose a mechanistic model in which autoimmune and inflammatory mechanisms intersect with thyrotoxicosis-driven hemodynamic stress to amplify endothelial dysfunction and cerebral demand–supply mismatch, precipitating or exacerbating symptoms in vulnerable MMD vasculature.[14,36,46]

## 2. METHODS

### LITERATURE SEARCH STRATEGY

We conducted a structured narrative literature review using the PubMed database to identify relevant studies examining the coexistence of Moyamoya disease (MMD) and Graves' disease (GD). The search strategy incorporated the terms "Moyamoya" and "Graves' disease," applied in combination. No formal protocol was registered. The search was limited to studies published in English and available up to January 2026. Duplicate records were removed prior to screening. Retrieved records underwent a stepwise selection process, including initial screening of titles and abstracts, followed by full-text eligibility assessment based on predefined inclusion and exclusion criteria. Studies were included if they reported original patient data (case reports or case series) describing individuals diagnosed with both MMD and GD. Given the rarity of the condition, all eligible case reports and case series were included without restriction on patient age or geographic region. Articles were excluded if they were not published in English or if they consisted solely of reviews without primary case data. In addition, the reference lists of all included articles were manually screened to identify any further relevant studies not captured in the initial search.

## 3. OVERVIEW OF REPORTED CASES

### RESULTS TABLE

A summary of all included studies is presented in Table 1, which outlines demographic characteristics, clinical presentation, thyroid status, imaging findings, management strategies, and outcomes across reported cases in the literature.

Across the literature, a consistent clinical pattern emerges. Most patients presented with ischemic cerebrovascular events, while hemorrhagic presentations were less common. Neurologic symptoms frequently occurred during periods of active thyrotoxicosis, supporting a temporal association between thyroid dysfunction and cerebrovascular instability.

GD was often diagnosed prior to or concurrently with MMD, although delayed recognition of either condition was also reported. Management strategies typically involved initial endocrine stabilization followed by surgical revascularization when indicated. Favorable neurologic outcomes were commonly reported after achieving euthyroid status, whereas recurrent events were most often associated with uncontrolled or relapsed hyperthyroidism.

Geographic distribution of reported cases suggests potential variability in co-occurrence patterns, with a higher proportion of cases originating from East Asian populations, where baseline MMD prevalence is also higher. While the available data are not sufficient to establish definitive population-level

**TABLE 1:**

| Reference | Year | No. of cases | Age/sex | Ethnicity | Temporal relationship between GD and MMD | Imaging findings (MMD) | Thyroid status & Laboratory findings | Clinical manifestation (Neurological manifestation/thyroid-related symptoms) | Endocrine treatment | Neurologic/surgical treatment | Outcome | Recurrence/Follow-up |
|---|---|---|---|---|---|---|---|---|---|---|---|---|
| Burgos-Sanchez 2025[1] | 2025 | 1 | 29y / F | Not reported | Known GD; presented with thyroid storm and multifocal ischemic strokes; MMD identified on imaging during acute presentation. | CT/MRI showed multifocal infarctions; CTA/MRA demonstrated bilateral ICA terminus narrowing with ACA/MCA involvement and collateral formation. | Elevated T3/T4 with undetectable TSH, consistent with thyroid storm. | Neurological: 2-week headaches; intermittent paresthesias, then persistent right-sided paresthesia, and right arm/leg weakness. Thyroid-related/systemic: Agitation, increased anxiety, palpitations, and tachycardia. | Medical treatment for thyroid storm (specific regimen not detailed). | Transferred to referral center where a combined direct + indirect bypass was performed. | Favorable outcomes. | Not reported |
| Guillaume Pierman et al.[40] | 2024 | 1 | 25y / F | Caucasian (Western European) | Hyperthyroidism and ischemic stroke at presentation; MMD confirmed on vascular imaging. | MRI showed bilateral MCA territory infarctions; MRA and angiography demonstrated stenosis of terminal ICAs and proximal ACA and MCA segments with typical moyamoya collateral networks. | Severe thyrotoxicosis: TSH <0.01 mU/L; FT4 59.61 pg/mL; FT3 25.17 pg/mL. TRAb 10.4 IU/L (elevated); TPOAb 485 IU/mL; TgAb 155 IU/mL. Thyroid scintigraphy: diffuse hyperuptake consistent with GD. | Neurologic: ischemic stroke (left sensorimotor deficit), later TIA, headaches, cognitive impairment, paresthesias. Thyroid-related: weight loss, tremor, palpitations, sweating, fatigue, exophthalmos. | Thiamazole, propranolol; later block-and-replace regimen with levothyroxine. | Aspirin (acute phase), enoxaparin, and cognitive rehabilitation; no revascularization surgery. | Complete resolution of initial sensorimotor deficit; persistent mild cognitive deficits improved with rehabilitation. | One TIA at 3 months; no recurrent stroke or hyperthyroidism at 10-year follow-up. |
| Yosuke Maezawa et al.[32] | 2024 | 1 | 18y / F | Japanese | Hyperthyroid symptoms for approximately 6 months and transient neurological symptoms for 1 month; GD diagnosed during hospitalization; MMD diagnosed subsequently based on imaging. | MRI and CT showed chronic infarctions; MRA demonstrated bilateral ICA occlusion with characteristic moyamoya collateral vessels. | FT3 >20.0 pg/mL, FT4 3.58 ng/dL, TSH 0.00 ?IU/mL, positive anti-TSH receptor antibody. | Neurological: Presented with loss of consciousness (~15 min), later generalized seizures/convulsions; history of transient left upper extremity numbness, and dysarthria. Thyroid-related/systemic: Palpitations, increased appetite, fatigability; exam showed tachycardia and diffuse thyroid swelling. | Thiamazole. | Diazepam and fosphenytoin. No antiplatelet therapy or revascularization required in this case. | Symptoms resolved with GD treatment; recovered to normal status during hospitalization; no further convulsive/ischemic attacks reported. | No relapse of seizures for 1 year after discharge while maintaining euthyroid status. |
| Kei Ito et al.[22] | 2024 | 459 | 73.6% female/ median age: 35 (adult onset 77.1%) | 99.1% Japanese (small % other East Asian) | Screening study; among MMD patients without prior thyroid disease, 6/459 (1.3%) were newly diagnosed with GD after evaluation; individual temporal relationship not specified. | Imaging details not specified. | fT3, fT4, TSH, TgAb, TPOAb, TRAb, TSAb, plus non-thyroid autoimmune markers (ANA, RF, RF-IgG, SS-A/SS-B, ?2GPI, aCL IgG) were screened. Results: 237/459 (51.6%) had ?1 abnormal marker. | Thyroid symptoms among overt thyrotoxicosis cases: 4/9 symptomatic (goiter/proptosis/sweating/weight loss), but 55.6% of cases were asymptomatic. For the 27 newly diagnosed thyroid disease patients, initial MMD presentation included ischemic stroke (13), hemorrhagic stroke (3), non-stroke symptoms (8: headache/epilepsy/psychiatric), and asymptomatic (3). | Not reported | Not reported | Screening detected occult thyroid disease and did not detect other autoimmune diseases; authors conclude routine thyroid screening may be meaningful, but routine non-thyroid autoimmune screening is not recommended without symptoms. | Not reported |
| Marino Hiruma et al.[14] | 2023 | 40 | Median age: 39y. 37 F and 3 M. | Not reported | MMD most commonly diagnosed within 1 year of GD onset (9/40, 22.5%); symptoms developed during hyperthyroidism; 4/7 discontinued treatment, one required revascularization after progression. | Imaging showed typical distal ICA and MCA involvement with moyamoya vessels; bilateral disease predominated; one progressed case demonstrated bilateral ICA stenosis consistent with Suzuki stage III. | Example onset labs (FT3/FT4/TSH/TRAb) showing suppressed TSH and high FT3/FT4 and TRAb in several cases (e.g., FT3 ~13–32.5+, FT4 ~4.6 to >7.8, TSH <0.01, TRAb up to >40). | Symptoms in 40 MMD+GD: headache (9), numbness (7), dysarthria (4), weakness (4), dizziness (3), tremor (2), consciousness disorder (2), epilepsy (1), visual field disorder (1), asymptomatic (14). Stroke subtype recorded in symptomatic: TIA (2), infarction (4), hemorrhage (3) (many "unknown" in records). | GD treatment status: medication (methimazole) 11 (27.5%), remission 12 (30%), definitive therapy 17 (RAI 12; thyroidectomy 5). | MMD management in 40 MMD+GD cases: Bypass surgery 19/40 (47.5%), medication 9/40, observation 7/40 (unknown 5). In 10 cases where thyroid status at MMD surgery known: surgery done after hyperthyroidism improved by medication (5) or radioactive iodine (5). | Not reported | Recurrence/outcome endpoints were not comprehensively provided. |
| Mufang Huang et al.[17] | 2023 | 1 | 19y / F | East Asian (Chinese) | GD preceded MMD; thyrotoxicosis diagnosed approximately 4 years before cerebrovascular event; MMD manifested during recurrence. | CT and MRI showed ischemic infarction with intraventricular hemorrhage; MRA demonstrated bilateral ACA and MCA stenosis or occlusion with surrounding moyamoya vessels. | Thyroid scintigraphy: diffuse increased 99mTc uptake consistent with GD; TSH suppressed, elevated thyroid hormones. | Neurologic: Acute ischemic stroke, intraventricular hemorrhage, and right limb paralysis. Thyroid-related: Long-standing thyrotoxicosis, sinus tachycardia, hypertension, goiter, exophthalmosi Other reported symptoms: progressive dental caries, alopecia, menstrual irregularity. | Hydrocortisone, PTU, and propranolol. | Conservative medical management only; no antithrombotic escalation reported; no surgical revascularization. | After 11 days of treatment, re-examination of head CT indicated absorption of ventricular hemorrhage and disappearance of infarction lesions. | Short-term follow-up during hospitalization showed no recurrence; long-term follow-up not reported. |
| Wei-Sheng Wang et al.[54] | 2023 | 1 | 35y / F | Not reported | Simultaneous diagnosis of GD and MMD with chorea as the initial manifestation. | MRI/MRA showed progressive stenosis of bilateral supraclinoid ICA, ACA (A1), and MCA (M1) segments with moyamoya collaterals; SPECT demonstrated bilateral frontal and left temporal hypoperfusion. | Overt thyrotoxicosis: TSH <0.005 μIU/mL, Free T4 5.35 ng/dL (elevated), T3 5.47 ng/mL (elevated). Positive anti-TSH receptor Ab (13.99 IU/L), anti-TPO Ab (277.5 IU/mL), thyroglobulin Ab positive. Thyroid US: bilateral diffuse goiter compatible with GD. | Neurological: Progressive chorea/choreoathetosis (initially left-dominant, later generalized), dystonia, dysmetria, dysdiadochokinesia, and dystonic gait. Thyroid-related symptoms: No typical hyperthyroid symptoms reported. | Short-term dexamethasone and long-term methimazole. | Steroid therapy. | Rapid and marked improvement of chorea and dystonia after 5 days of dexamethasone. | No recurrence reported; long-term outcome not provided. |

**TABLE 1:** Continued..

| Reference | Year | No. of cases | Age/sex | Ethnicity | Temporal relationship between GD and MMD | Imaging findings (MMD) | Thyroid status & Laboratory findings | Clinical manifestation (Neurological manifestation/thyroid-related symptoms) | Endocrine treatment | Neurologic/surgical treatment | Outcome | Recurrence/Follow-up |
|---|---|---|---|---|---|---|---|---|---|---|---|---|
| Nuno Neves et al.[35] | 2023 | 1 | 36y / F | Caucasian | MMD diagnosed at stroke presentation; GD identified during etiological workup; patient was euthyroid with positive thyroid autoantibodies; GD considered a contributing condition. | MRI showed acute and chronic infarctions with progressive atrophy; angiography demonstrated bilateral supraclinoid ICA stenosis with ACA/MCA involvement, hypertrophied lenticulostriate vessels, and leptomeningeal collaterals; perfusion imaging showed reduced cerebral blood flow. | Euthyroid. TRAb: 4.8 IU/L (positive). TPO-Ab: 1145 IU/L (markedly elevated). Tg-Ab: 1158 IU/mL (markedly elevated). GD diagnosed despite normal thyroid hormone levels. | Neurological: Acute ischemic stroke, right lower limb monoparesis, hypoesthesia, progressive behavioral disturbance, cognitive decline, and frontal lobe dysfunction. Thyroid-related: Exophthalmos, no overt thyrotoxic symptoms (euthyroid). Other systemic: Confirmed antiphospholipid antibody syndrome. | No antithyroid medication reported. GD managed conservatively (euthyroid state). | Warfarin; no revascularization surgery. | Persistent neurological deficits, progressive cognitive decline, worsening frontal lobe atrophy. | 3-year follow-up: No new acute stroke events. Radiological progression of cerebral atrophy. |
| Cai Gao-Rui et al.[8] | 2022 | 1 | 25y / F | Not reported | GD diagnosed preoperatively with a 3-year history of untreated goiter; MMD diagnosed postoperatively after ischemic stroke. | CT and MRI demonstrated bilateral ischemic infarctions; MRA showed MCA occlusion with additional intracranial arterial stenoses. | Severe thyrotoxicosis: TSH <0.01 mIU/L, T3 >10 nmol/L, T4 >320 nmol/L, FT3 41.1 pmol/L, FT4 >100 pmol/L. Markedly positive antibodies: anti-TPO 352 IU/mL, anti-thyroglobulin 3652 IU/mL, TRAb 14.1 IU/L. Thyroid US: diffuse thyroid enlargement. | Neurological: Acute postoperative ischemic stroke (aphasia, facial weakness, left upper limb disability). Thyroid-related: Diffuse goiter, mild exophthalmos; no detailed hyperthyroid symptom profile reported. | Antithyroid drugs and transferred to neurosurgery. | Specific revascularization procedure not reported. | Developed acute ischemic cerebral infarction 3 days postoperatively; stabilized and transferred for neurosurgical management. | No long-term neurological or MMD follow-up reported; recurrence not described |
| Ramírez-Quiñones et al.[41] | 2022 | 1 | 34y / F | Amerindian | Simultaneous diagnosis of GD-related thyrotoxicosis and MMD during hospitalization for ischemic stroke. | MRI showed bilateral anterior circulation infarcts with leptomeningeal "ivy sign"; CTA/MRA and angiography demonstrated bilateral ICA stenosis/occlusion with ACA and MCA involvement and absent right-sided flow. | Severe thyrotoxicosis: TSH <0.005 IU/mL; FT4 6.13 ng/dL. Autoantibodies positive: anti-thyroglobulin 474.8 IU/mL, anti-TPO 600 IU/mL, anti-TSH receptor Ab 5.72 IU/mL | Neurological: Acute ischemic stroke with left hemiparesis, facial asymmetry, and dysarthria. Thyroid-related: Palpitations, fatigue, weight loss, cachexia, moist skin, and bilateral exophthalmos. | Methimazole. | Antiplatelet therapy and high-dose statin; no surgical revascularization. | Clinical improvement at 3 months with residual mild hemiparesis; modified Rankin Scale improved from 4 to 2. | No recurrence reported; 3-month follow-up documented with functional improvement. |
| Gill et al.[10] | 2022 | 1 | 43y / F | Not reported | Known GD prior to admission with untreated hyperthyroidism; presented with ischemic stroke; MMD diagnosed by angiography; thyroid storm developed during hospitalization. | Serial MRI showed progression from small left frontal infarct to bilateral frontal infarctions; angiography demonstrated bilateral distal ICA occlusion with moyamoya vessels and poor collateralization. | Thyroid storm. Labs at deterioration: TSH <0.01 μU/mL; T3 >8.0 ng/mL (elevated); Free T4 9.47 pmol/L; TSH receptor antibody 37.10 U/L (elevated). Burch–Wartofsky score 85. | Neurological: Acute ischemic stroke (right hemiparesis, later bilateral weakness), dysarthria, decreased consciousness, and seizure. Systemic/thyroid-related: Thyroid storm with fever, severe tachycardia, atrial fibrillation, and hypertension. | Methimazole, iodine, and hydrocortisone. | Hydration, antiplatelet therapy, anticonvulsants, ICU care; no revascularization surgery performed. | Thyroid storm controlled; neurological deficits improved with rehabilitation. | 6-month follow-up: alert mental status, mini-mental state examination test score of 27/30, near-complete motor recovery (upper V/IV, lower V/V); no recurrence reported. |
| Paulo Ribeiro Nóbrega et al.[37] | 2022 | 1 | 43y / F | Not reported | GD diagnosed 3 years prior; neurological evaluation for progressive symptoms revealed ischemic lesions; subsequent imaging confirmed MMD. | MRI showed bilateral frontal and parietal cystic encephalomalacia in watershed zones; also pons/middle cerebellar peduncle/cerebellar atrophy. MRA demonstrated progressive bilateral ICA stenosis/occlusion with lenticulostriate collaterals and "puff of smoke" moyamoya vessels. | Not reported | Neurological: 2-year history of mild gait imbalance, ataxic gait, inability to tandem stance; hyperreflexia, positive Hoffmann/Babinski reflex; slow/dysmetric saccades, amd mild gaze-evoked nystagmus. Thyroid-related/systemic: Bilateral proptosis; Turner syndrome features and premature ovarian failure were noted. | Not reported | Not reported | Not reported | Not reported |
| Hikaru Nakamura et al.[34] | 2021 | 1 | 19y / F | Not reported | GD diagnosed at age 15; MMD diagnosed 5 years later after ischemic stroke. | MRI showed acute infarction in right occipital and parietal lobes; MRA demonstrated supraclinoid ICA, MCA, and ACA stenosis with basal moyamoya collaterals and cervical ICA "champagne bottle" appearance; SPECT showed reduced perfusion in right MCA territory. | At GD diagnosis (age 15): FT3: 7.80 pg/dL (elevated). FT4: 2.94 ng/dL (elevated). TSH: 0.007 mIU/mL (suppressed). TSAb: 317% (positive). At time of stroke: FT3: 2.91 pg/dL. FT4: 1.34 ng/dL. TSH: 1.048 mIU/mL. | Neurological: Acute ischemic stroke and left-sided hemiparesis. Thyroid-related: Prior thyrotoxicosis, weight loss, fever, diarrhea at GD onset. No thyroid storm at time of stroke. | Thiamazole (methimazole). | Superficial temporal artery-Middle cerebral artery (STA–MCA) bypass and encephalo-duro-myo-synangiosis (EDMS). | Good recovery and no new postoperative neurological deficits. | No recurrence of stroke reported. Duration of follow-up not precisely specified. |
| Hiroto Ito et al.[21] | 2019 | 1 | 37y / F | Not reported | Initial ischemic stroke occurred during thyrotoxicosis without evident ICA stenosis; recurrent TIAs 5 months later with thyrotoxicosis and progressive ICA stenosis; subsequent gradual progression with mild thyrotoxicosis. | Serial imaging showed progression from mild ICA stenosis to diffuse stenosis with collateral formation; angiography demonstrated ICA narrowing with characteristic morphology; vessel-wall imaging showed inflammatory changes with enhancement. | At first stroke: FT3 10.58 pg/mL, FT4 2.70 ng/dL, TSH 0.01 ?U/mL; anti-TPO Ab 148.0 IU/mL, TRAb 8.3 IU/mL. Other labs: leukopenia; anti-SSA/SSB positive; TAT elevated 2.5 ng/mL; CRP/ESR negative. | Neurological: First episode progressive right arm weakness with infarcts. Second episode: recurrent transient weakness of right arm/leg (multiple TIAs). Thyroid/systemic: Intermittent palpitations and sweating, but no obvious exophthalmos or enlarged thyroid on exam. | Potassium iodide, methimazole, and IV methylprednisolone. | Heparin, warfarin, argatroban, clopidogrel, and aspirin; no revascularization surgery performed. | After achieving euthyroid state improved flowin left ICA/MCA/ACA on follow-up MRA and catheter angiography showed improved blood flow and mild improvement of terminal ICA stenosis. | Follow-up described to 2 years after recurrence with serial MRA/angiography showing improved flow; recurrence attacks stopped after IV methylprednisolone and antiplatelets; enhancement of vessel wall persisted despite improvement. |

**TABLE 1:** Continued..

| Reference | Year | No. of cases | Age/sex | Ethnicity | Temporal relationship between GD and MMD | Imaging findings (MMD) | Thyroid status & Laboratory findings | Clinical manifestation (Neurological manifestation/thyroid-related symptoms) | Endocrine treatment | Neurologic/surgical treatment | Outcome | Recurrence/Follow-up |
|---|---|---|---|---|---|---|---|---|---|---|---|---|
| Ryosuke Tashiro et al.[30] | 2019 | 136 | Mean age 43.1 (range 11–78); Sex not fully detailed | Japanese | Not reported. | MMD diagnosed by criteria with bilateral terminal ICA steno-occlusive changes and collateral networks; Suzuki stage distribution analyzed without group differences. | Not reported | Not reported | Not reported | Not reported | Not reported | Not reported |
| Wunderle . et al[55] | 2017 | 1 | 40y / F | Not reported | Poorly controlled GD for approximately 4 years with persistently suppressed TSH; prior neurological symptoms attributed to other causes; presented with stroke; imaging findings consistent with MMD. | CT showed bilateral MCA infarctions; MRA and angiography demonstrated diffuse ICA and M1 narrowing consistent with moyamoya vasculopathy. | TSH <0.05 mIU/L (also reported as persistently <0.01 mIU/L on multiple visits). Free T4 6.39 ng/dL. TPOAb 687 IU/mL. Autoimmune workup for vasculitis/APS negative (ANA, C-ANCA, P-ANCA, antiphospholipid antibodies). | Neurological: Recurrent episodes of dizziness/paresthesias/tingling, near-syncope; current presentation with left facial numbness/cramping, drooling, aphasia; prior day difficulty speaking, vision changes, and tongue numbness. Examination: Somnolent, incomprehensible speech, and right facial droop. Thyroid/systemic: Conspicuous exophthalmos, large goiter; tachycardia, and elevated blood pressure. | Methimazole and atenolol. | Steroid therapy. | Diagnostic correction (vasculitis to moyamoya syndrome) prevented prolonged immunosuppression; outpatient neurosurgery follow-up planned. | Not reported |
| Qian Zhang et al.[57] | 2017 | 42 | mean age 34.9 ± 16.5years/ 57.1% female and 14/42 <18y. | Chinese | Study-level data: quasi-MMD associated with comorbidities; autoimmune thyroid disease present in 8/42 cases, including GD in 6/42 and Hashimoto disease in 2/42; temporal relationship not specified. | Angiography and MRA demonstrated bilateral moyamoya vessels in most cases; Suzuki stages ranged from 0 to VI across hemispheres. | Not reported | The presenting symptoms at onset included TIA 35.7%, infarction 33.3%, hemorrhage 26.2%, headache 2.4%, and seizure 2.4%. Thyroid-related symptom details not provided. | Not reported | Not reported | Not reported | Not reported |
| Yi-Yi Xuan et al.[56] | 2017 | 1 | 26y / F | Not reported | GD treated for approximately 8 years; intracranial vasculopathy consistent with MMD identified during evaluation for systemic symptoms, without confirmatory angiography. | CT showed deep white matter infarction; MRA demonstrated bilateral ICA narrowing with ACA/MCA hypoplasia or occlusion and "puffy smoke-like" vessels in saddle area/cisterna ambiens/ parietal region. | Thyroid on admission: FT3: 5.56 pmol/L (near upper-normal), FT4 16.75 pmol/L(upper-normal), TSH: 0.01 uIU/mL (suppressed), TRAb: 5.16 IU/L(elevated). | Recurrent fever, auricular chondritis, ocular inflammation (red/painful eyes), and arthritis in multiple joints. Neurological exam was negative. | Iodine-131, prednisone, cyclophosphamide, and azathioprine. | Medical therapy; no neurosurgical revascularization reported. | Symptoms rapidly relieved; inflammatory markers normalized; no adverse events. | Follow-up reported through 12.5 months. No flare reported. |
| Yasufumi Gon et al.[12] | 2017 | 1 | 30y / F | Japanese | GD diagnosed 3 weeks prior; subsequent acute ischemic stroke associated with cerebrovascular steno-occlusive disease in the context of GD. | MRI showed "rosary-like watershed infarcts"; MRA demonstrated ICA occlusion; vessel-wall imaging showed inflammatory enhancement; SPECT demonstrated regional hypoperfusion in right basal ganglia and right talamus. | TSH ?0.010 ?U/mL, FT3 ?25.0 pg/mL, FT4 ?8.0 ng/dL. Antithyroid antibodies elevated: TPO-Ab 87 IU/mL, TRAb 18.5 IU/L. | 4-day intermittent transient dysarthria and limb shaking of left leg when standing. Neurological exam: Paralytic dysarthria, left central facial nerve palsy, and left hemiparesis. Thyroid-related/systemic: Diffuse goiter and severe hypertension on admission. | Not reported | Clopidogrel and STA–MCA bypass. | Bypass performed due to medical-treatment resistance; post-operative neurologic outcome details not reported. | Not reported |
| Nirav H. Shah et al.[46] | 2016 | 8 | All female. Mean age: 32. Age range: 19–48. | Hispanic / Latin American: 7 patients. White, non-Hispanic: 1 patient | GD/thyrotoxicosis present at stroke in all cases; duration ranged from new diagnosis to 12 years; ischemic events occurred during active thyrotoxicosis. | MRA performed in all patients and angiography in most; findings included bilateral terminal ICA stenosis with frequent proximal ACA and MCA involvement and typical moyamoya collateral vessels; all cases had ischemic infarction without hemorrhage. | All patients thyrotoxic at presentation. TSH: Undetectable in all cases. T4: Markedly elevated (mean total T4 ? 9.9 ng/dL). Thyroid antibodies: Positive in 5/8 (TSH receptor, TPO, or thyroglobulin antibodies). | Neurological: Acute ischemic stroke (100%). MCA territory infarctions most common. No intracranial hemorrhage in index cases. Thyroid-related: Goiter in all patients. Ophthalmopathy in 7/8 (Except patient-5). Clinical thyrotoxicosis at presentation. | All patients received a combination of antithyroid treatment with either methimazole or propylthiouracil (PTU). ?-blockers (propranolol): 6/8. Steroids: 4/8 during acute ischemia. | Medical therapy, extracranial–intracranial bypass, and antiplatelet therapy. | Clinical improvement in majority. No significant difference in outcomes between medical therapy alone vs. medical and surgical prophylaxis. Modified Rankin Scale generally improved or stabilized. | No recurrent strokes once thyrotoxicosis was controlled. One recurrent stroke occurred due to noncompliance with antithyroid therapy. No patients lost to follow-up. |
| Julian Choi et al.[6] | 2016 | 1 | 31y / F | Hispanic | GD diagnosed 1 year prior; antithyroid therapy discontinued 5 weeks before admission; presentation with thyrotoxicosis and ischemic stroke; MMD diagnosed during hospitalization. | MRI showed acute infarction; CTA/ MRA demonstrated bilateral ICA occlusion or severe stenosis with MCA involvement; angiography confirmed bilateral moyamoya disease with posterior collateral flow; Suzuki stage II (right) and stage V (left). | Thyrotoxicosis: TSH < 0.005 IU/mL, T4 23.07 µg/dL, Total T3 > 651 ng/dL. Thyroid ultrasound: diffusely enlarged thyroid with heterogeneous echotexture and increased vascularity. | Neurological: Progressive right-sided hemiparesis, unsteady gait and falls, seizures (simple partial to generalized tonic–clonic), and ischemic stroke. Thyroid-related / systemic: Palpitations, sinus tachycardia, exophthalmos, visible diffuse goiter, and thyrotoxic state. | Methimazole and propranolol. | Antiplatelet therapy, antiepileptic drugs, and bilateral encephalomyosynangiosis. | Immediate postoperative neurologic improvement. Postoperative recurrent seizures. Recurrent marked thyrotoxic state. Septic–cardiogenic shock. Death. | Fatal outcome on postoperative day 6. Thus, no long-term follow-up possible. |

**TABLE 1:** Continued..

| Reference | Year | No. of cases | Age/sex | Ethnicity | Temporal relationship between GD and MMD | Imaging findings (MMD) | Thyroid status & Laboratory findings | Clinical manifestation (Neurological manifestation/thyroid-related symptoms) | Endocrine treatment | Neurologic/surgical treatment | Outcome | Recurrence/Follow-up |
|---|---|---|---|---|---|---|---|---|---|---|---|---|
| Shou-Chen Ren et al.[42] | 2016 | 1 | 12y / M | Chinese | Thyrotoxic symptoms present for approximately 1 year; simultaneous diagnosis of GD and MMD during admission for acute neurological deterioration; ischemic event occurred during thyrotoxicosis. | MRI showed multifocal infarctions; MRA and DSA demonstrated severe bilateral terminal ICA stenosis with near-complete ACA/MCA occlusion and typical moyamoya collateral network. | On admission: TSH <0.001 μU/mL, FT3 29.17 pmol/L, FT4 35.99 pmol/L; thyroid antibodies positive: TRAb positive, TPOAb 396.44 U/mL TGAb 134.56 U/ml. Coagulation: FVIII 261.6%, vWF 224.2% (markedly elevated) while other coagulation parameters largely normal. Antibodies stayed high during follow-up; vWF/FVIII fluctuated with thyroid function. | Neurological: Rapidly progressive mild quadriplegia, aphasia, urinary incontinence, recurrent brief convulsions, facial paralysis, hyperreflexia, and bilateral positive Babinski reflex. Thyroid-related/systemic: Irritability, tremor, excessive sweating, frequent palpitations; enlarged thyroid; hypertension and tachycardia at admission. | Thiamazole and metoprolol. | EDAS. | Thyroid function normalized and neurological symptoms improved significantly. vWF/F:VIII decreased with thyroid normalization. | 20-month follow-up: Serial monitoring every 3 months (neurological symptoms, imaging, thyroid labs/antibodies, coagulation). High thyroid autoantibodies persisted; other coagulation parameters remained normal range; vWF/FVIII tracked with thyroid function. No recurrence described during follow-up. |
| Jian-Bin Chen et al.[2] | 2015 | 29 MMD patients diagnosed with GD, 25 patients included in follow-up analysis. | Mean age at MMD onset: 34.8 ± 11.1 (range 18–65). Sex distribution: Male/female ? 1:3.1 (6M, 19F in 25 patients). | Chinese (East Asian) | GD diagnosed based on thyroid function testing in patients with MMD; neurological events frequently occurred during hyperthyroidism; progression and recurrent strokes associated with thyroid hormone fluctuations or relapse. | MRA and angiography demonstrated terminal ICA stenosis or occlusion with moyamoya collateral vessels; bilateral involvement predominated with progressive angiographic stages; MRI and functional imaging showed ischemia, hemorrhage, and reduced perfusion. | Elevated T3, T4, fT3, fT4, suppressed TSH, and thyroid uptake and TSH receptor antibody testing. | Neurological: Ischemic stroke, TIA, intracranial hemorrhage, recurrent strokes (up to 5 episodes per patient), and progressive neurological deficits. Thyroid-related: Palpitations, fatigue, bulimia, and typical hyperthyroid symptoms prior to endocrine treatment. | Methimazole, PTU, and radioactive iodine therapy. | STA–MCA bypass and EDAS. | Disease progression in 40% of MMD-GD patients. Stroke incidence: 48% (significantly higher than MMD without GD). One death due to recurrent intracranial hemorrhage. GD identified as an independent risk factor for MMD progression. OR = 5.97 (95% CI 1.24–33.76). | Mean follow-up: 106.4 ± 48.6 months (range 6–216 months). Recurrent strokes: Occurred in 4 patients. All unilateral MMD cases with GD progressed to bilateral disease. High recurrence risk despite controlled thyroid function. |
| Bikei Ryu et al.[44] | 2015 | 8 | 1 M and 7 F | Not reported | Simultaneous diagnosis in 4/8 cases; MMD preceded GD in 2/8; GD preceded MMD in 2/8. | Angiography confirmed MMD with Suzuki stages II–IV; MRI showed infarction in some cases; perfusion imaging demonstrated reduced cerebral blood flow. | At ischemic onset in 6 thyrotoxic cases: fT4 4.81–10.30, fT3 13.08–31.90, TRAb 3.5–83.8 IU/L; TRAb elevated in 7/8 overall (one long-treated GD case not elevated). At surgery: fT3 optimized to mean 3.02 (range 1.01–4.87) and fT4 mean 1.09 (range 0.41–1.68). | All presented with cerebral ischemia. Symptoms included arm numbness, dysarthria, hemiparesis; several had MRI-confirmed infarcts. Thyrotoxic symptoms in thyrotoxic cases included hypertension, tachycardia, fever, tremor, palpitations, sweating, and restlessness. One patient developed thyroid storm during pre-operative management with cerebral infarction. | Thiamazole, radioablation, and propranolol. | Medical therapy and STA–MCA double bypass. | No post-op neurological aggravation; no surgical complications reported. At 3 months, excellent outcomes: mRS ?2 in all cases. | Follow-up reported to 3 months post-op. At 3 months, excellent outcomes: mRS ?2 in all cases. No post-op ischemic/hemorrhagic complications described within this follow-up window. |
| Jian-Bin Chen et al.[4] | 2015 | 142 | Mean age 31.5 (range 5–65) / 69% female. | Predominantly Han Chinese (91.6%), also Yi, Zang, Qiang, other minorities | Temporal relationship not specified; higher prevalence of GD reported among MMD patients compared to the general Chinese population. | Angiography confirmed MMD with predominantly bilateral involvement. | Not reported | Neurological: TIA 33.1%, infarction 28.2%, headache 9.9%, hemorrhage 7.8%, memory loss 4.9%, cognitive decline 6.3%, seizure 4.2% of cases and 5.6% of cases were asymptomatic. Thyroid symptom details were not reported. | Not reported | Not reported | Not reported | Not reported |
| Waqas Jehangir et al.[24] | 2015 | 1 | 26y / F | Hispanic | Known GD prior to neurological event; developed acute deficits during hospitalization; imaging revealed moyamoya-like stenosis; presentation not clearly related to thyrotoxicosis. | MRA demonstrated bilateral ICA stenosis with additional posterior circulation involvement and diffuse vascular narrowing; no evidence of vasculitis on workup. | Not reported | Presented with cough and shortness of breath for 5 days. In hospital developed sudden right arm numbness, right facial droop, and slurred speech. | Not reported | Tissue plasminogen activator administered; no revascularization surgery described. | Symptoms temporarily improved after tPA; further course managed at receiving center (details not provided). | Follow-up not reported (patient transferred). |
| Byoungho H. Noh et al.[18] | 2015 | 1 | 16y / F | Not reported | Presented with diabetic ketoacidosis and hyperthyroidism; developed thyroid storm after treatment initiation, followed by multiple cerebral infarctions. | MRI showed multiple acute infarctions; MRA demonstrated bilateral distal ICA and MCA stenosis consistent with MMD. | TSH <0.001 U/mL, fT4: 9.1 ng/dL (later >12 at worst), T3: 7.24 ng/mL. Thyroid-stimulating immunoglobulin: 16.04 IU/L, anti-TPO Ab: 254.8 U/mL, anti-GAD Ab: 215.72 U/mL; other autoimmune antibodies negative. | Neurological: Right hemiplegia during storm. Thyroid-related/systemic: Tachycardia; then became hot/diaphoretic, agitated/confused, Burch-Wartofsky score 65; had goiter and dehydration, vomiting/epigastric pain, polyuria/polydipsia. | Methimazole and hydrocortisone. | Antithrombin III + fresh frozen plasma; no cerebral bypass reported. | Neurological symptoms completely resolved within 1 month; free T4 normalized within 8 weeks. | No recurrence reported. |

**TABLE 1:** Continued..

| Reference | Year | No. of cases | Age/sex | Ethnicity | Temporal relationship between GD and MMD | Imaging findings (MMD) | Thyroid status & Laboratory findings | Clinical manifestation (Neurological manifestation/thyroid-related symptoms) | Endocrine treatment | Neurologic/surgical treatment | Outcome | Recurrence/Follow-up |
|---|---|---|---|---|---|---|---|---|---|---|---|---|
| Jian-Bin Chen et al.[3] | 2016 | 384 (316 bilateral MMD; 68 unilateral MMD) | Unilateral: 67.6% female; Bilateral: 51.3% female. Mean age at onset: unilateral 38.9 ± 11.5, bilateral 37.3 ± 13.7 | Unilateral group: Han 91.2%, Yi 2.9%, Zang 1.5%, Qiang 1.5%, other 2.9% | Not specified; prevalence/comparison study without individual-level temporal data. | Imaging showed variable unilateral or bilateral anterior circulation involvement with ischemic or hemorrhagic presentations; angiographic patterns consistent with MMD. | Not reported | Presenting symptoms compared between groups. No thyroid symptom details. TIA (unilateral 27.9% vs bilateral 21.8%), headache (14.7% vs 13.0%), motor weakness (14.7% vs 12.7%), seizure (5.9% vs 5.1%), asymptomatic (13.2% vs 23.7%). | Not reported | Not reported | NR (study focuses on prevalence/association, no outcomes or interventions analyzed). | Not reported |
| Bon D. Ku et al.[27] | 2015 | 1 | 42y / F | Korean | Presented with thyrotoxicosis and MMD; underwent revascularization with poor treatment adherence; progressive vasculopathy and recurrent thyroid storm culminated in fatal infarction during uncontrolled thyrotoxicosis. | MRI showed progressive ischemic lesions; angiography demonstrated supraclinoid ICA occlusion with collateral networks and progressive contralateral stenosis; follow-up imaging showed worsening infarction with poor leptomeningeal collaterals. | First visit thyroid labs: T3: 5.5, T4: 14.0, TSH <0.03 (thyrotoxicosis). One year later (thyrotoxic crisis): T3: 7.5, T4: 18.0, TSH: <0.03; antibodies markedly elevated: thyroglobulin Ab: 871.5 U/mL, antimicrosomal Ab: 2,850 U/mL, TSH receptor Ab: 492.1%; thyroglobulin antigen: 64.5 ng/mL. | Neurological: Initial left-hand clumsiness; later episode with fever, confusion, right-sided weakness; recurrent episodes of dyspnea/hyperventilation followed by right-sided numbness/clumsiness, then declining mental status and generalized tonic–clonic seizures. Thyroid-related/systemic: Palpitations, dyspnea, warm moist skin, goiter ~2× normal, lid retraction/slight exophthalmos, fine tremor, and sweating. | Treated for thyroid storm (specific drug regimen not detailed). | EDAS. | Fatal; developed multiple large infarctions with herniation; died of cerebral herniation 17 days after admission; thyrotoxicosis remained uncontrolled after stroke. | Death; no long-term recurrence data beyond this course. |
| Jun Ni et al.[36] | 2014 | 12 | All female. Mean age: 33.3 ± 12.7 years. Age range: 11–55. | Not reported | GD preceded or was concurrent with MMD; all cases had active thyrotoxicosis at ischemic events; no cases of MMD preceding GD. | MRI and MRA performed in all patients with angiographic confirmation in some; findings included bilateral or asymmetric ICA stenosis with ACA and MCA involvement, occasional posterior circulation involvement, and moyamoya collateral vessels without atherosclerotic plaque. | All patients thyrotoxic at time of ischemic stroke/TIA. Thyroid hormones: Elevated T3/T4. TSH: Suppressed in all cases. Thyroid antibodies: Thyroid peroxidase antibody and/or thyroglobulin antibody elevated in all 12 patients. Inflammatory and autoimmune markers: Normal. Homocysteine: Normal | Neurological: Ischemic stroke: 9 patients. TIA: 4 patients. Dizziness: 1 patient. Chorea (initial manifestation): 1 patient. No hemorrhagic strokes. Thyroid-related: Clinical thyrotoxicosis in all patients. Symptoms consistent with GD (not individually detailed). | Antithyroid drugs (specific agents were not named). | Antiplatelet therapy. No revascularization surgery reported in this series. | Generally favorable neurological outcomes. Neurological improvement correlated with thyroid function control. No hemorrhagic complications reported. | Two patients experienced recurrent ischemic attack. Recurrence occurred approximately 6 months after antithyroid drug withdrawal. No recurrence reported with continued thyroid treatment. |
| Chong Kun Cheon et al.[5] | 2014 | 2 | Case 1: 12y / F. Case 2: 15y / F | Not reported | GD diagnosed first, followed by MMD in both cases. | Imaging demonstrated ICA and MCA stenosis or occlusion with collateral vessels; MRI showed ischemic or hemorrhagic lesions; SPECT demonstrated regional hypoperfusion and reduced vascular reserve. | Case 1: Euthyroid T3: Elevated (213.36 ng/dL). FT4: Normal. TSH: Suppressed. TSH receptor antibody: Markedly elevated. Case 2: Near-euthyroid / subclinical hyperthyroid. T3 & FT4: Within normal range. TSH: Suppressed. TSH receptor antibody: Elevated. | Case 1: Neurologic: Syncope precipitated by hyperventilation. Thyroid-related: History of GD, no acute thyrotoxic symptoms. Case 2: Neurologic: Transient right-sided hemiparesis, headache, and facial palsy. Thyroid-related: Goiter. | Methimazole. | EDAS. | Resolution and marked improvement of neurological symptoms. No further ischemic or neurologic events reported. | No recurrence of neurologic symptoms. Patients remained stable at last follow-up (duration was not reported). |
| Takafumi Shimogawa et al.[48] | 2014 | 1 | 43y / F | Japanese | Acute ischemic stroke with simultaneous diagnosis of GD and MMD during the same admission; euthyroid state achieved after treatment; vascular findings remained unchanged. | MRI showed infarction at the left posterior limb of internal capsule; MRA/3D-CTA and angiography demonstrated bilateral distal ICA and proximal ACA/MCA stenosis with moyamoya vessels in left basal ganglia; Suzuki stage I–III; SPECT showed impaired vascular reserve. | TSH 0.015 μU/mL, FT3 26.42 pg/mL, FT4 4.37 ng/dL, TSH receptor Ab 36.7%(positive). Thyroid US: diffuse goiter; scintigraphy positive. | Neurologica: Right-sided weakness on waking, mild right hemiparesis, and dysarthria. Thyroid-related/systemic: 6-month history of fatigue and weight loss, tachycardia, carotid bruit; no obvious goiter/exophthalmos on exam. | Methimazole and potassium iodide. | Ozagrel, edaravone, heparin, aspirin, warfarin, STA–MCA anastomosis, EDAS, and EMS. | Neurologic deficits resolved by 2 months. Post-op MRA showed patent bypass; IMP-SPECT showed improved cerebral blood flow and vascular reactivity in left MCA territory. No further ischemic events reported. | 4-year follow-up: Maintained euthyroid state and had no additional cerebral ischemic events. |
| Akiko Ishigami et al.[20] | 2014 | 1 | 22y / F | Japanese | Presented with acute left MCA infarction and GD; neurological deterioration occurred during hospitalization with subsequent identification of thyrotoxicosis; clinical improvement followed antithyroid therapy, with later radiographic progression of MMD. | Initial imaging showed left MCA infarction without collaterals; follow-up angiography demonstrated development of moyamoya vessels with progressive arterial stenosis at origin proximal M1 and right ACA; PET showed misery-perfusion phenomenon in left MCA territory. | At admission: FT3: 12.6 pg/mL, FT4: 6.7 ng/dL, TSH <0.01 mIU/mL, TSH receptor Ab 15.8 IU/L, TS-Ab 885%. Day 23 thyrotoxicosis: FT3 30.2 pg/mL, FT4 >7.7 ng/dL. Thyroid scintigram: diffuse goiter with high uptake. | Neurological: Sudden right-sided weakness, aphasia, left conjugate deviation, right hemiparesis, and sensory loss; worsened to complete right leg paralysis by day 8 with infarct growth. Thyroid-related/systemic: Exophthalmos and enlarged thyroid lobesnoted on exam. | Thiamazole. | Edaravone, heparin, and STA–MCA bypass. | Hemiparesis became milder after starting thiamazole. Reported free from recurrent stroke post-bypass. | No recurrent stroke for 3 years after initial onset. |

**TABLE 1:** Continued..

| Reference | Year | No. of cases | Age/sex | Ethnicity | Temporal relationship between GD and MMD | Imaging findings (MMD) | Thyroid status & Laboratory findings | Clinical manifestation (Neurological manifestation/thyroid-related symptoms) | Endocrine treatment | Neurologic/surgical treatment | Outcome | Recurrence/Follow-up |
|---|---|---|---|---|---|---|---|---|---|---|---|---|
| Desheng Li et al.[31] | 2013 | 21 | Age range: 7–62. Mean age: 44. Sex distribution: 16 females (76.2%). 5 males (23.8%). Adults: 15/21 (71.4%). Pediatric patients: 6/21 (28.6%). | Chinese (East Asian) | MMD symptoms developed during hyperthyroidism in 18/21 patients (85.7%); GD generally preceded or coincided with neurological manifestations; stroke recurrence observed during relapse. | CT and MRI demonstrated predominantly ischemic infarctions; angiography showed bilateral ICA involvement with Suzuki stages distributed as stage II (n=12), stage III (n=9), stage IV (n=13), and stage V (n=3); PET demonstrated regional hypometabolism. | Thyrotoxic state: 18/21 patients. Euthyroid: 3 patients. Elevated thyroid hormones (T3, T4, FT3, FT4), suppressed TSH, thyroid uptake studies, and TRAb testing. Immune findings: Elevated immune complexes in 3 patients. Positive dsDNA antibody in 1 pediatric case. | Neurological manifestations: Ischemic stroke (dominant presentation), limb weakness (unilateral or alternating bilateral), aphasia, headache, and blurred vision. One asymptomatic case. Thyroid-related symptoms: Palpitations, fatigue, and hypermetabolic symptoms (e.g., bulimia, heat intolerance). Symptoms typically present during hyperthyroid phase. | Methimazole, PTU, and radioactive iodine. | Medical therapy and EDAS. | Good recovery (mRS 0–1): 17/20 patients (85%). Mild–moderate disability (mRS 2–3): 3/20 patients. Overall neurological improvement in all followed patients. Surgical treatment was associated with reduced stroke recurrence, improved cerebral perfusion. Authors emphasized the importance of thyroid control to prevent recurrence. | Follow-up completed in 20 patients. Mean follow-up: 24 months (range 2–77 months). Stroke recurrence: 2 patients experienced new infarction during hyperthyroidism relapse. Both recovered and later underwent additional surgery. |
| Hotaka Kamasaki et al.[25] | 2013 | 1 | 14y / M | Japanese | MMD diagnosed with concurrent thyrotoxicosis; thyroid autoantibodies initially negative, becoming positive approximately 1 month later, consistent with evolving GD. | MRI showed small anterior white matter infarctions; MRA demonstrated bilateral carotid stenosis with moyamoya collaterals; SPECT showed reduced regional perfusion. | Initial labs: TSH <0.1, FT4: 4.31 ng/dL, FT3 10.08 pg/mL; TPOAb positive; TGAb normal; TRAB negative and TSAB negative. After stopping meds: rebound thyrotoxicosis (FT4: 7.16) with TRAB 20.6% and TSAB 182% (positive). Thyroid US: heterogeneous echotexture. 99mTc scan: diffuse high uptake 23.1%. | Neurological: Progressive right arm weaknessworsening over 12 months. Thyroid-related/systemic: Tremor, mild exophthalmos, soft goiter, fever, tachycardia, elevated systolic blood pressure, later palpitations/fatigue, and history suspicious for chronic thyrotoxic symptoms (fatigue, excess eating, diarrhea, sweating). | Thiamazole, potassium iodide, and bisoprolol. | EDAS. | Thyrotoxic symptoms improved within 1 week after treatment; later GD was confirmed; retreatment led to remission again; reported good prognosis. | Followed weekly after stopping methimazole/potassium iodide; relapse at 2 weeks with antibody conversion; course figure shows follow-up to day 119; no report of recurrence after remission. |
| Shaneela Malik et al.[33] | 2011 | 1 | 23y / F | Not reported | Concurrent GD and MMD with active thyrotoxicosis at neurological presentation. | MRI showed acute and chronic bilateral cerebral infarctions; angiography demonstrated multivessel intracranial occlusive disease consistent with MMD. | Active thyrotoxicosis at presentation. Specific hormone values not numerically reported. | Neurological: Fluctuating confusion. Right arm paresis. Ischemic stroke. Thyroid-related: Symptomatic thyrotoxicosis. | Antithyroid therapy after acute stabilization. Plasmapheresis used during acute thyrotoxic phase | Aspirin (acute phase) and encephalomyosynangiosis performed after thyroid control. | Prolonged neurologic stability. Improvement after combined endocrine control and revascularization. | No recurrence. |
| Sakiko Suzuki et al.[49] | 2011 | 2 | Case 1: 38y / M. Case 2: 43y / F. | Japanese | GD diagnosed before or concurrently with MMD; neurological symptoms occurred during uncontrolled thyrotoxicosis; diabetes mellitus preceded or coexisted with GD in both cases. | Case 1 showed bilateral terminal ICA stenosis with MCA involvement; Case 2 showed unilateral ICA stenosis consistent with quasi-MMD; MRI demonstrated watershed or deep white matter infarctions; SPECT showed reduced cerebral blood flow with impaired reactivity. | Suppressed TSH. Markedly elevated FT3 and FT4. Elevated TSH receptor antibodies (TRAb, TSAb). | Neurological: Transient ischemic attacks, hemiparesis, and cerebral infarction. Thyroid-related: Symptoms of hyperthyroidism (not completely detailed) and diffuse toxic goiter. Metabolic: Type 2 diabetes mellitus and hyperglycemia. | Thiamazole. | STA–MCA double bypass. | Improvement of cerebral ischemic symptoms. Improved cerebral perfusion on postoperative SPECT. Neurologically stable. | No recurrence of ischemic symptoms. Stable at follow-up (duration not precisely specified). |
| Shigeo Ohba et al.[39] | 2011 | 1 | 46y / F | Not reported | GD treated surgically at age 34 with long-term euthyroid status; TIA occurred 6 years later; medications discontinued at age 46; recurrent ischemic symptoms developed approximately 1 month later during hypothyroidism, leading to MMD diagnosis. | MRI showed lacunar infarction; angiography demonstrated bilateral terminal ICA stenosis with moyamoya collaterals; SPECT showed reduced cerebral blood flow. | During symptom recurrence after stopping meds: FT3 1.1 pg/mL (low), FT4 0.4 ng/dL (low), TSH 53.8 ?U/mL (high) ? hypothyroid; levothyroxine resumed. Later follow-up euthyroid labs reported: FT3 2.5, FT4 1.14, TSH 3.40. | Neurologica: Transient weakness and numbness of right upper limb; prior TIA history. Also reported muscle pain, feeling cold, weight gain at the hypothyroid episode. Thyroid/systemic symptoms aligned with hypothyroidism during recurrence (cold sensation/weight gain). | Levothyroxine and thiamazole. | Antiplatelet therapy, STA–MCA bypass, and EMS. | Improved perfusion via STA on angiography; SPECT showed improved blood supply vs pre-op. Overall reported as favorable/good outcome. | Followed for 2 years: occasional TIAs, but frequency decreased; euthyroid state maintained. |
| Hiroshi Tokimura et al.[52] | 2010 | 2 | Case 1: 19y / F Case 2: 52y / F (mother and daughter). | Japanese | Case 1: thyrotoxicosis diagnosed first; cerebral infarction occurred immediately after thyroidectomy for GD; Case 2: GD diagnosed 18 years prior; hemorrhagic event occurred long after thyroidectomy with normal thyroid function at admission. | Case 1 showed bilateral ICA and ACA/MCA occlusion with moyamoya collaterals (Suzuki stage V); Case 2 showed ICA stenosis with ACA/MCA involvement and hemorrhagic lesion (Suzuki stage III). | Case 1: TRAb 86.2%, TSH 0.03 mU/mL, FT3 30.0 pg/dL, FT4 6.0 ng/dL (thyrotoxic). Post-thyroidectomy at admission:slight hypothyroidism (TSH 39.51; FT3 2.4; FT4 0.83). Case 2: Labs normal at admission for hemorrhage. | Neurological: Case 1: Right-hand numbness/dysesthesia. Case 2: Sudden left hemiparesis at onset of hemorrhage; later no paresis but left upper quadrantanopsia reported. Thyroid symptoms in history: tachycardia/exophthalmos (Case 1), tachycardia/sweating (Case 2). | Thyroidectomy. | STA–MCA bypass. | Both returned to normal daily life after revascularization; no perioperative ischemic events reported in Case 1; Case 2 had no postoperative neurologic deficits reported. | Case 1: No recurrence of cerebral ischemia for 5 years after surgery. Case 2:Post-op stable; scheduled for additional revascularization (long-term recurrence not reported). |
| Hidenori Endo et al.[7] | 2010 | 4 | 42y / F, 36y / M, 55y / F, 34y / F | Japanese | Mixed timing: 2/4 simultaneous GD and MMD; 1/4 MMD preceding GD with later hemorrhage; 1/4 GD preceding MMD by 30 years. | Angiography demonstrated bilateral and unilateral steno-occlusive lesions; SPECT showed prior right watershed infarct, reduced cerebral blood flow and vascular reserve; postoperative imaging showed improved perfusion and collateralization. | Initial to pre-op: Case 1: FT3: 6.67 to 2.27 pg/dL, FT4: 2.70 to 0.80 ng/dL, TSH <0.01 to <0.01. Case 2: FT3: 29.9 to 3.38, FT4: 8.16 to 1.09, TSH: 0.05 to 0.05. Case 3: FT3: 30.0 to 5.01, FT4: 6.00 to 1.69, TSH 0.03 to 0.05. Case 4: FT3: 22.4 to 2.65, FT4: 8.71 to 0.44, TSH: 0.05 to 0.05. | Cerebrovascular events, 3 TIA, 1 intracerebral hemorrhage; 3/4 thyrotoxic at onset of cerebrovascular event; ischemic symptom frequency decreased after antithyroid therapy. | Thiamazole. | STA–MCA anastomosis, EDMS, and dural pedicle insertion. | Post-op: 1 symptomatic hyperperfusion resolved with nicardipine. Others uneventful. Discharged within 20 days; returned to normal daily life. | All remained neurologically stable. |

**TABLE 1:** Continued..

| Reference | Year | No. of cases | Age/sex | Ethnicity | Temporal relationship between GD and MMD | Imaging findings (MMD) | Thyroid status & Laboratory findings | Clinical manifestation (Neurological manifestation/thyroid-related symptoms) | Endocrine treatment | Neurologic/surgical treatment | Outcome | Recurrence/Follow-up |
|---|---|---|---|---|---|---|---|---|---|---|---|---|
| Ran Lee et al.[39] | 2009 | 1 | 19y / F | Korean | GD diagnosed first; MMD diagnosed 4 years later; neurological events occurred during thyrotoxicosis. | MRI showed chronic infarctions with bilateral MCA and ICA stenosis; angiography demonstrated bilateral supraclinoid ICA occlusion with absent ACA/MCA visualization and transdural collaterals; SPECT showed multifocal cortical hypoperfusion. | TSH: 0.001 ?IU/mL (suppressed). T3: 681 ng/dL (markedly elevated). Free T4: > 6.0 ng/dL. Thyroid aspiration: diffuse hyperplasia consistent with GD At neurologic presentation: TSH: 0.13 ?IU/mL. T3: 221.9 ng/dL. Free T4: 2.46 ng/dL. TSH receptor antibody: 40.09 IU/L (positive). | Has Down Syndrome. Neurological: Episodic right hemiparesis, central-type right facial palsy, slurred speech, nystagmus, and prior prolonged weakness lasting about 1 month. Thyroid-related: Goiter, bilateral exophthalmos, and history of thyrotoxicosis. | PTU. | EMS and EDAS. | Significant neurological improvement. Motor power recovered to grade 5 in right upper and lower extremities. Improved cerebral perfusion on follow-up angiography. | No recurrence of neurological symptoms. Follow-up duration: 2 years. |
| Béatrice Garcin et al.[9] | 2008 | 1 | 19y / F | Ivorian | GD diagnosed at age 18 with poor treatment adherence; chorea developed during severe thyrotoxicosis; symptoms improved with treatment but relapsed with recurrent hyperthyroidism; resolved after thyroidectomy. | MRI showed left anterior putamen and head of left caudate lesions; MRA and angiography demonstrated bilateral supraclinoid ICA stenosis with left ACA and both MCAs involvement and moyamoya collaterals. | Free T4 >100 pmol/L, TSH <0.001 mUI/L, thyroid-stimulating antibodies positive 21.1 UI/L. | Neurological: Progressive chorea (predominantly facial; symmetric upper limbs, worse in sustained posture), balance impairment, dysarthria, impaired tandem gait, and mild bradykinesia/slow alternating movements. Thyroid-related/systemic: Diffuse goiter; thyrotoxicosis signs including warm moist skin and tachycardia. | Carbimazole, levothyroxine, propranolol, later thyroidectomy. | Not reported | Clinical signs of thyrotoxicosis and neurological symptoms subsided within a few weeks; at 3 months neurological exam normal and thyroid tests normal. | Two relapses in the following year with recurrence of hyperthyroidism and chorea. |
| Ai-Ling Shen et al.[47] | 2006 | 1 | 23y / F | Not reported | Simultaneous diagnosis of GD-associated thyrotoxicosis and MMD during initial hospitalization. | MRI showed small infarcts in right centrum semiovale; MRA and angiography demonstrated bilateral supraclinoid ICA stenosis or occlusion with ACA and MCA involvement and collateral supply from posterior circulation. | Severe thyrotoxicosis: T3 5.76 nmol/L (elevated), FT4 >111 pmol/L (elevated), TSH <0.03 mU/L (decreased); microsomal antibody titer 1:1024; thyroid ultrasound and cytology consistent with autoimmune thyroid disease. | Neurologic: recurrent right carotid TIAs, ischemic stroke, left hemiparesis, migraine-like headaches. Thyroid-related: sinus tachycardia, cervical bruits, hyperthyroid state. | PTU and propranolol. | Aspirin later switched to ticlopidine; no surgical revascularization performed. | Patient was discharged with minimal weakness in the left limbs one week after admission. Gradual neurological improvement. | Recurrent ischemic stroke occurred 3 weeks after initial event (associated with increased antithyroid dose and phenylpropanolamine exposure); was stable thereafter. 2-year follow-up showed only mild residual weakness of the left hand. |
| Takahiro Sasaki et al.[45] | 2006 | 3 (2 definite and 1 probable MMD) | Case 1: 27y/F; Case 2: 16y/F; Case 3: 36y/F | Japanese | Case 1: GD diagnosed with recurrent TIAs, improved with treatment, recurred with nonadherence; Case 2: TIAs for approximately 6 months, hyperthyroidism identified during evaluation; Case 3: GD for 2 years with poor control, acute event during thyrotoxicosis. | Multiple cases showed ischemic or hemorrhagic lesions on MRI with reduced perfusion on SPECT; angiography demonstrated bilateral or unilateral ICA stenosis with ACA and MCA involvement and characteristic collateral vessels. | Case 1: TSH 0.08 ?U/mL; fT3 5.5; fT4 1.4; TRAb 56.4%. Autoimmune/vasculitis labs negative (ANA, dsDNA, aCL, p-/c-ANCA). Case 2: TSH 0.01; fT3 9.4; fT4 3.1; autoimmune markers negative. Case 3: TSH <0.1; fT3 4.0; fT4 1.5; TRAb 2.9%; TGAb <0.3; TPO Ab 65; ANA positive, other autoantibodies negative. | Case 1: Recurrent dizziness + left hemiparesis, later left-arm flaccidity, dysarthria, headache; exam: left upper-limb paresis, hyperreflexia/positive Babinski reflex. Case 2: Recurrent TIAs with left hemiparesis and faintness; no neuro deficits at admission. Case 3: Sudden aphasia during poor thyroid control; exam: hyperreflexia/Babinski on right; carotid bruit. GD signs (reported variably): goiter/exophthalmos prominent in Case 1; no goiter in Case 2; goiter and carotid bruit in Case 3. | Antithyroid drugs. | Encephaloduroarteriosynangiosis (EDAS) and medical therapy. | Case 1:Hemiparesis improved after antithyroid meds; ischemic attacks suppressed under euthyroid state. Case 2: EDAS performed to prevent further attacks (course described without acute deficits at admission). Case 3:After regular antithyroid meds, MRA findings unchanged and no ischemic attacks reported. | No further ischemic attacks; follow-up duration was not specified. |
| Hsu S-W et al.[16] | 2006 | 1 | 40y / F | Caucasian | GD preceded MMD; GD diagnosed 6 months earlier; MMD presented during thyroid storm 3 weeks after radioactive iodine ablation. | CT showed multifocal bilateral ischemia; angiography demonstrated severe bilateral distal ICA occlusion with ACA and MCA involvement, reduced flow, delayed transit, and posterior collateral circulation. | Severe thyrotoxicosis / thyroid storm: Free T4 18 ng/dL (elevated), TSH 0.22 μU/mL (decreased); autoimmune antibody testing not performed. | Neurologic: Severe headache, rapid progression to coma, global cerebral ischemia, and brain death. Thyroid-related/systemic: thyroid storm, nausea, vomiting, tremor, neck pain, hypertension, and tachycardia. | Prior radioactive iodine ablation; specific medications were not detailed. | Supportive intensive care; no revascularization or neurosurgical intervention. | Fatal: Rapid neurologic deterioration and brain death; death on hospital day 2 after withdrawal of life support. A postmortem examination was not conducted. | NA (death during acute hospitalization). |
| Meredith R. Golomb et al.[11] | 2005 | 1 | 10y / F | White (Polish, Hungarian, German, and English ancestry) | Ischemic stroke due to MMD prompted evaluation leading to GD diagnosis; thyroid-related symptoms had been present for approximately 2 years prior. | MRI showed multifocal infarctions; MRA and angiography demonstrated bilateral distal ICA stenosis with MCA involvement, nonvisualization of right MCA and left A1, and prominent lenticulostriate collaterals consistent with MMD. | Suppressed TSH (<0.005–0.013 ?IU/mL). Markedly elevated thyroid hormones: Total T4 up to 22.1 ?g/dL. Free T4 up to 8.8 ng/dL. Total T3 570 ng/dL. Free T3 20.3 pg/mL. Positive antithyroglobulin antibody. Positive antithyroperoxidase antibody. Thyroid uptake scan: diffuse uptake (70%). Mildly elevated anticardiolipin IgG antibody. | Neurological: Acute ischemic stroke. Left facial, arm, and leg weakness. Mild persistent left hemiparesis and headaches prior to presentation. Thyroid-related: Increased fatigability, heat intolerance, loose stools, fine tremor, tachycardia, and goiter on examination. | Radioactive iodine ablation and levothyroxine. | Aspirin, verapamil, and bilateral cranial revascularization with pial synangiosis. | No recurrent ischemic events. Resolution of headaches after surgery. Stable neurological status postoperatively. | Follow-up duration: 15 months post-surgery. No stroke recurrence during follow-up. |

**TABLE 1:** Continued..

| Reference | Year | No. of cases | Age/sex | Ethnicity | Temporal relationship between GD and MMD | Imaging findings (MMD) | Thyroid status & Laboratory findings | Clinical manifestation (Neurological manifestation/thyroid-related symptoms) | Endocrine treatment | Neurologic/surgical treatment | Outcome | Recurrence/Follow-up |
|---|---|---|---|---|---|---|---|---|---|---|---|---|
| So-Hyang Im et al.[19] | 2005 | 4 | All female. Age range at presentation: 22-25. | Not reported | Cases 1, 3, and 4: simultaneous diagnosis of GD and MMD; Case 2: MMD diagnosed first at age 14, GD diagnosed 2 years later; ischemic events occurred during thyrotoxicosis in all cases. | Angiography demonstrated bilateral ACA and MCA stenosis/occlusion with typical moyamoya collaterals; MRI showed cerebral infarction in all cases; SPECT demonstrated impaired perfusion and reduced vascular reserve; Suzuki stage III–IV. | Elevated T3 and FT4. Suppressed TSH. High-titer TSH receptor antibodies. Thyroid scintigraphy: Diffuse toxic goiter with increased tracer uptake. | Neurological: Cerebral infarctions and recurrent TIAs in all cases. Fixed neurological deficits (Cases 1 & 3). Thyroid-related: Palpitations, heat intolerance, goiter, and exophthalmos. | Methimazole, PTU, propranolol, atenolol, and radioactive iodine. | STA–MCA anastomosis combined with encephalomyosynangiosis (EMS) and/or EDAS. | All patients were neurologically stable. Improved cerebral perfusion on postoperative angiography and SPECT. Resumed normal daily life. | Follow-up duration: 8 months–7 years. No recurrent ischemic events after surgery and thyroid control. |
| Andrew Jea et al.[23] | 2005 | 16 (All Down syndrome patients) | 10F / 6M average age at onset 9.3y (range 1–29). | Not reported | Not reported. | MRI/CT showed infarctions in most cases; angiography demonstrated bilateral ICA and branch involvement with posterior circulation contribution; postoperative imaging showed new collateral formation and improved revascularization. | Not reported | All ischemic—TIA-like episodes were present in 10 cases (62.5%) and stroke was present in 6 cases (37.5%) (common symptom hemiparesis/hemiplegia; alternating hemiparesis noted in several). Thyroid-related symptoms were not detailed. | Not reported | Aspirin, pial synangiosis, and STA–MCA bypass. | Early complications included subdural hematoma, seizures, and new infarctions within 30 days. | Long-term follow-up average 67.6 months (range 6–146). No strokes occurred beyond the perioperative 30-day window; annual post-op MRI/MRA showed no new infarcts. No worsening neurologic status except 1 patient with seizure disorder and chronic hypocalcemia becoming dependent. |
| Ufuk Utku et al.[53] | 2004 | 1 | 45y / F | Not reported | Moyamoya-like intracranial stenoses occurred in the setting of autoimmune GD-related encephalopathy; vascular changes were reversible after immunotherapy. | Initial MRI was normal; MRA showed severe bilateral ICA stenosis with distal vessel involvement; follow-up imaging demonstrated resolution after treatment. | Admission: FT3: 13.8 pg/dL, FT4: 5.07 ng/dL, TSH: 0.001 IU/mL; anti-TPO 1000 IU/mL. Thyroid scan: bilaterally diffuse hyperplasia. | Neurological: Subacute encephalopathy (drowsiness, hallucinations, disorientation), urinary/fecal incontinence, strokelike episodes with right arm/leg weakness, dysarthria, and increased deep tendon reflex (DTRs). Thyroid-related/systemic: Diffuse goiter, fine tremor, minimal exophthalmos, and tachycardia. | PTU, propranolol, IV methylprednisolone, and radioactive iodine. | Not reported | Neurologic status improved dramatically after steroids and plasmapheresis; angiographic abnormalities resolved. | Follow-up documented at 4 months: mild residual hyperreflexia/tremor; MRA normal. No recurrence reported. |
| Ji Youn Kim et al.[26] | 2001 | 1 | 37y / F (31 weeks pregnant) | Korean | GD diagnosed 3 years prior with intermittent treatment; during admission for thyrotoxicosis-induced cardiomyopathy, seizure prompted imaging leading to MMD diagnosis. | MRI showed chronic infarction with encephalomalatic change and underlying schizencephaly; MRA demonstrated bilateral supraclinoid ICA occlusions with MCA involvement consistent with MMD. | TSH <0.02 mU/mL, total T3: 306 ng/dL, free T4: 3.9 ng/dL. | Neurological: First seizure on day 16. Presented with exertional dyspnea worsening for 3 days; signs of thyrotoxicosis (warm moist skin, fine tremor, goiter), atrial fibrillation with rapid ventricular response, pulmonary edema. | PTU, dexamethasone, furosemide, digoxin, propranolol, and enalapril. | Medical therapy, no neurosurgical revascularization described. | Cardiac function reversed with euthyroid state; neurological outcome after seizure not detailed beyond diagnosis. | Not reported |
| Carlos Leno et al.[30] | 1998 | 1 | 21y / M | Not reported | GD diagnosed during admission for ischemic event in a patient with Down syndrome; MMD confirmed on angiography during the same evaluation. | CT showed infarction, septum pellucidum cyst, and slight basal ganglia calcifications. Angiography demonstrated supraclinoid ICA stenosis with reduced MCA flow, absent ACA visualization, and prominent lenticulostriate arteries. | Total T4: 21.2 ?g/dL (high), total T3: 583 (high), resin T3 uptake index 1.34 (high), TSH <0.5 mUI/L (low). Antithyroglobulin Ab negative, antimicrosomal Ab positive (1:400). | Neurological: Sudden-onset left arm weakness, then left leg weaknes. Exam shpwed moderate left hemiparesis with increased DTRs on left. Thyroid-related/systemic: Tachycardia and bilateral exophthalmos. | Antithyroid drugs. | Aspirin; no revascularization surgery reported. | Residual moderate disability in left limbs from infarction. | No further cerebrovascular disorders reported; persistent mild autoimmune markers mentioned. |
| Beatriz E. Tendler et al.[51] | 1997 | 2 | Case 1:37y / F Case 2:47y / F | Case 1:Hispanic case 2:Caucasian | Case 1: ischemic event occurred approximately 16 days after radioactive iodine therapy, with thyroid storm symptoms around day 9; Case 2: MMD diagnosed approximately 10 years before GD. | CT showed infarction; angiography demonstrated bilateral supraclinoid ICA stenosis/occlusion with characteristic collateral "puff of smoke" vessels. | Case 1:TSH <0.1 ?IU/mL; TT3 528 ng/dL. After radioactive iodine with thyroid storm: TSH <0.1, total T4 26.1 ?g/dL. Later TT3 289 ng/dL. Case 2 (GD at diagnosis): TSH <0.1 ?IU/mL; T4 9 ?g/dL; TT3 406 ng/dL; FT4 index 10.4; later recurrence: TSH <0.1, T4 15.9 ?g/dL, TT3 289 ng/dL, FT4 index 19; TSI 1844%. | Case 1: Post-RAI fever/headache, diffuse numbness/weakness, then left-hand paresthesias and left arm weakness with imaging-confirmed infarct. Case 2: Initial moyamoya presentation at 38y with dysarthria and accelerated hypertension; later Graves symptoms included weight loss, diffuse goiter with bruit, exophthalmos; later diplopia/weight loss with recurrent hyperthyroidism. | Case 1: PTU and metoprolol initially; then radioactive iodine; thyroid storm treated with PTU, steroids, and beta-blockers; later subtotal thyroidectomy. Case 2: PTU and atenolol; intensified PTU, pre-op iodine, and hydrocortisone, later subtotal thyroidectomy; recurrence treated with PTU. | Aspirin; no revascularization surgery reported. | Case 1: Neurologic improvement within 24 hours; full neurologic recovery in 2 weeks. Case 2: Tolerated thyroidectomy well; later treated again and reported as doing well. | Not reported |
| Kenji Kushima et al.[28] | 1991 | 2 | Case 1: 26y / F Case 2: 22 y / F | Both cases are Japanese (East Asian) | Case 1: GD preceded MMD, events during thyrotoxicosis with recurrence during relapse; Case 2: GD preceded MMD, event during active thyrotoxicosis with progression under persistent hyperthyroidism. | CT showed cerebral infarctions; angiography demonstrated bilateral ICA narrowing with characteristic moyamoya collateral vessels. | Case 1: Severe thyrotoxicosis: T3 7.7 nmol/L (elevated), FT4 >66 pmol/L (elevated), TSH <1.0 mU/L. Case 2: Thyrotoxicosis: T3 5.5 nmol/L (elevated), T4 265 nmol/L (elevated), TSH 1.0 mU/L; high titer TSH receptor antibodies. | Case 1: Neurologic: Recurrent ischemic stroke, hemiparesis (right then left), speech disturbance, headache, and sensory deficits. Thyroid-related: hyperthyroid symptoms during relapses. Case 2: Neurologic: Ischemic stroke, left hemiparesis, and motor aphasia. Thyroid-related: Goiter, exophthalmos, hyperhidrosis, and weight loss. | Antithyroid drugs. | Conservative medical management; no surgical revascularization reported. | Case 1: Neurological deficits improved with normalization of thyroid function. Case 2: Persistent neurological injury noted; stabilization reported. | Case 1: Recurrent cerebral infarction occurred with recurrence of thyrotoxicosis; improvement after resumption of antithyroid therapy. Case 2: Thyrotoxicosis recurred after treatment interruption; long-term neurological follow-up not detailed. |

risk estimates, this trend may support a lower threshold for thyroid function screening in patients of East Asian origin or in regions with higher reported concurrence. Future studies incorporating population-based stratification will be essential to refine screening recommendations.

## 4. PATHOPHYSIOLOGICAL LINK BETWEEN MMD AND GD

### 4.1 Autoimmunity and Shared Immunological Pathways

Autoimmunity is one of the main proposed links between GD and MMD. The pathophysiology of MMD remains incompletely understood but is hypothesized to involve autoimmune mechanisms. GD is a type II hypersensitivity (antibody-mediated) autoimmune hyperthyroidism in which IgG autoantibodies stimulate the TSH receptor. Several studies have described an "autoimmune vasculopathy" pattern, where patients with MMD have higher rates of thyroid autoantibodies even when they are euthyroid.[34] Thyroid antibodies and TSH have been associated with internal carotid stenosis and Moyamoya vasculopathy, as well as stroke outcomes.[14,36,46] In case series, thyroid autoantibodies (including thyroid peroxidase and thyroid gland antibodies) are commonly elevated,[36] suggesting that immune activation may play a role beyond thyroid hormone levels alone. Some authors propose that TRAb could have direct effects on blood vessels because TSH receptors are present in vascular tissue and are involved in angiogenesis and smooth muscle proliferation; overstimulation could contribute to intracranial arterial narrowing and endothelial dysfunction.[40] Finally, shared T-cell dysregulation has been suggested, and there are reports of moyamoya-like vasculitic changes improving with immunomodulatory treatments such as steroids and plasma exchange, supporting an immune-mediated contribution to the vascular disease.[17,45] Collectively, these findings suggest that autoimmune processes in GD may not only coexist with MMD but actively participate in the initiation or acceleration of Moyamoya vasculopathy through direct vascular effects.

### 4.2 Thyrotoxicosis-Induced Hemodynamic Stress

In addition to autoimmune overlap, thyrotoxicosis may worsen MMD by creating a hyperdynamic, high-demand state that narrowed intracranial arteries cannot adequately accommodate. Several reports have noted that strokes/TIAs and worsening vasculopathy often occur during active hyperthyroidism, and they emphasize controlling thyrotoxicosis (such as with antithyroid medication and beta-blockers) to reduce recurrence, especially when missed medications lead to repeat thyrotoxic episodes and strokes.[34,46] Proposed mechanism includes hyperthyroidism increases cerebral oxygen use and cerebral blood flow, which may increase hemodynamic stress on vessel walls, and it can also increase sympathetic activity, promoting intracranial vasoconstriction and stenosis.[14] Studies also report increased cerebral blood flow and higher MCA flow velocity during thyrotoxicosis (including correlation with serum T3), and severe thyrotoxicosis may increase sensitivity to sympathetic simulation, which can worsen cerebral perfusion and trigger ischemic events.[47] Clinical improvement after returning to euthyroid status supports this hemodynamic trigger, and some authors suggest catecholamine sensitivity and vasospasm may contribute to infarction during hyperthyroid states.[40] Finally, because the carotid circulation is heavily influenced by sympathetic nerves from the superior cervical ganglion, and hyperthyroidism has been linked to increased carotid stiffness, sympathetic–hemodynamic effects may be an important way GD contributes to moyamoya-related strokes.

### 4.3 Endothelial Dysfunction and Inflammation

Thyroid hormone excess in GD may contribute to the development of Moyamoya vasculopathy by affecting endothelial function and promoting vascular remodeling. One proposed effect is altered vascular reactivity and arterial wall properties during thyrotoxicosis, which may increase ischemic risk when superimposed on pre-existing intracranial stenosis.[34] Some papers describe endothelial-related changes in hyperthyroidism, including increased nitric oxide production and relaxation of vascular smooth muscle, supporting altered endothelial signaling during thyrotoxic states.[29] Over time, these endocrine and vascular effects are observed alongside structural arterial changes, such as intimal thickening, subendothelial fibrosis, and smooth muscle proliferation, that align with progressive stenosis.[6] In addition, shared vascular risk mechanisms (including hyperhomocysteinemia/atherosclerosis-related pathways) are proposed as contributors to endothelial dysfunction and progression of cerebrovascular disease in thyrotoxic MMD patients.[41] These overlapping endothelial and inflammatory pathways further support a shared biological substrate linking GD and MMD, rather than two independent disease processes occurring in parallel.

### 4.4 Genetic Factors

A genetic association between GD and MMD has been suggested, although no definite shared mutation has been identified. Some authors suggest a shared genetic background because a MMD susceptibility locus (8q23, MYMY3/MM3) lies near a thyroid autoimmunity locus (8q24, thyroglobulin) implicated in both Hashimoto's and GD, and familial clustering (including a mother–daughter pair) raises the possibility of inherited susceptibility even when a specific locus cannot be identified.[17,40,46] Taken together, these mechanisms support a two-hit model in which autoimmune-mediated endothelial injury and vascular remodeling establish a chronic susceptibility, while thyrotoxicosis-induced hemodynamic and metabolic stress acts as a synergistic trigger, precipitating ischemic events in patients with impaired cerebrovascular reserve.

## 5. Diagnostic Considerations

### 5.1 Recognizing MMD in Patients with GD

Although MMD is rare in GD, MMD should be suspected in patients with GD who develops new neurologic symptoms, such as chronic headaches, focal deficits, or other CNS symptoms, especially when symptoms occur during hyperthyroid periods.[14] When these symptoms appear, early neuroimaging is important, reported cases have been diagnosed using brain magnetic resonance angiography and cerebral

angiography, and patients underwent revascularization soon after diagnosis with good clinical outcomes.[5] Because GD may be associated with more frequent ischemic attacks or accelerated progression in some patients, authors recommend early imaging follow-up along with strict thyroid control.[34] In more severe presentations (e.g., thyroid storm with diabetic ketoacidosis), early recognition is emphasized as critical because the combination of thyroid crisis and cerebrovascular events in MMD can markedly increase morbidity and mortality, making early diagnosis and treatment crucial.[44] Clinically, new neurologic symptoms in GD—particularly during thyrotoxicosis—should prompt early vascular imaging to exclude MMD.

### 5.2 Recognizing GD in Patients with MMD

Recognizing GD in patients with MMD is important because thyrotoxicosis can act as a trigger for cerebrovascular events and may worsen vasculopathy. In reported cases, cerebrovascular accidents occurred when patients were thyrotoxic, and the increase in cerebral blood flow and other cerebral hemodynamic changes during thyrotoxicosis were proposed as the trigger for these vascular attacks.[28] Because thyrotoxicosis may promote vasculopathy progression, authors emphasize that medical correction of thyrotoxicosis should be first-line, and that non-compliance can lead to relapse of neurologic symptoms and more ischemic events.[54] Similarly, thyroid hormone levels have been linked to vascular stiffness, and neurologic improvement has been reported after antithyroid treatment, supporting the idea that patients with arterial stenoses and GD are at risk for ischemic cerebrovascular events and should have careful thyroid evaluation and control.[29] Sudden surges in thyroid hormone should be avoided, and overall careful control of thyroid function is essential in these patients.[29]

An important clinical question is whether routine screening for GD should be performed in patients with MMD, particularly in the absence of overt thyrotoxic symptoms. Based on the synthesized data, targeted screening may be most appropriate in patients presenting with ischemic events without clear precipitating factors, those with recurrent or unexplained neurologic symptoms, and individuals from populations in which co-occurrence has been more frequently reported.

### 5.3 Imaging Characteristics

Across the included studies, MMD is defined on vascular imaging (DSA/MRA/CTA) by progressive steno-occlusive disease of the distal/terminal (often supraclinoid) internal carotid arteries. Frequently, these occlusions extend into the proximal ACA and MCA branches, notedly with A1 and M1 involvement or occlusion, with development of an abnormal basal collateral network. This network is typically referred to as "moyamoya vessels", net-like collateral vessels in a "puff-of-smoke" pattern that may be described as typical MMD vasculature on angiography.[18] When reported, angiographic severity is summarized using Suzuki staging (commonly stage II–V across affected hemispheres). Parenchymal imaging such as brain MRI and CT most often shows ischemic infarction (with some cohorts explicitly reporting high infarct prevalence), while a smaller subset report hemorrhagic presentations (including intraventricular hemorrhage in some cases). Finally, physiologic imaging (e.g., SPECT/PET/perfusion studies) is used in multiple reports to demonstrate hypoperfusion, reduced vascular reserve, hypometabolism, or "misery perfusion" corresponding to symptomatic vascular territories, supporting a hemodynamic mechanism in addition to structural stenosis.[18,34]

## 6. Disease Interaction During Acute Neurologic Events

Case reports and series consistently demonstrate a close temporal relationship between active hyperthyroidism and acute ischemic events in patients with Moyamoya vasculopathy. In the cohort reported by Li et al.,[31] 18 of 21 patients developed neurologic symptoms during a hyperthyroid state. Similarly, Ni et al. described all 12 patients as thyrotoxic at the time of ischemic presentation,[36] and Shah et al. reported overt thyrotoxicosis in all patients at stroke onset. Individual case reports further reinforce this phenomenon.[46] Several case reports describe neurologic deterioration occurring in the setting of uncontrolled thyrotoxicosis, thyroid storm, or abrupt endocrine destabilization.[6,27] In these instances, clinical decline coincided with systemic metabolic stress rather than structural vascular progression, suggesting that acute endocrine imbalance may precipitate hemodynamic compromise in patients with limited cerebrovascular reserve.

Several physiologic mechanisms may explain the association between thyrotoxicosis and ischemic events in MMD. Hyperthyroidism increases basal metabolic rate, heart rate, systemic oxygen consumption, and cardiac output. Cerebral metabolic demand rises as well. In the context of MMD, where cerebral perfusion relies on stenotic vessels and collateral networks with impaired cerebrovascular reserve,[19,44] this increase in metabolic demand may exceed available blood flow, leading to ischemia.

Furthermore, hyperventilation, dehydration, tachycardia, and blood pressure fluctuations have been described during thyrotoxic episodes.[16,27] Hyperventilation-induced hypocapnia may provoke cerebral vasoconstriction, further reducing cerebral blood flow in territories with limited reserve. The interaction of these factors supports a demand–supply mismatch mechanism in which metabolic stress and impaired cerebrovascular reserve converge to precipitate acute neurologic events.

Thyroid storm represents the extreme of the metabolic spectrum and has been associated with abrupt neurologic deterioration. Hsu et al. reported rapidly progressive bilateral cerebral infarctions during thyroid storm, resulting in fatal cerebral edema.[16] Noh et al. described multiple acute infarctions developing during thyroid storm in a patient with concurrent diabetic ketoacidosis.[38] Additionally, Gill et al. reported expansion of infarction and neurologic worsening during hospitalization complicated by thyroid storm.[10] In these cases, large-vessel embolism was not identified, and deterioration appeared temporally linked to endocrine decompensation, illustrating how acute thyroid storm may

destabilize previously compensated collateral-dependent cerebral circulation.

Beyond hemodynamic stress, autoimmune and endothelial factors likely act synergistically with metabolic disturbances to drive the coexistence and progression of GD-associated MMD. Ohba et al. noted that although the mechanism underlying intracranial arterial stenosis in patients with GD remains unclear, immune-mediated processes may play a role.[39] Li et al. suggested that the pathogenesis of MMD complicated by GD may involve genetic and immune factors.[31] Population-based analyses have further supported an association between autoimmune abnormalities and moyamoya vasculopathy.[4] Zhang et al. also emphasized that the mechanism underlying their coexistence remains undefined.[57]

In addition to immune hypotheses, endothelial activation and coagulation abnormalities during active thyrotoxicosis may contribute to vascular instability. Ren et al. reported markedly elevated von Willebrand factor and factor VIII levels during active thyrotoxicosis, with values fluctuating in parallel with thyroid hormone levels.[42] These findings suggest endothelial activation and a potential hypercoagulable state during uncontrolled hyperthyroidism.

## 7. Management Strategies

Management follows a three-staged approach as rapid endocrine stabilization, hemodynamic optimization, and delayed revascularization once euthyroid status is achieved.

### 7.1 Endocrine Management

Given the temporal association between thyrotoxicosis and ischemic events in previously reported cases, endocrine stabilization prior to surgical intervention is a central component of management in patients with concurrent MMD and GD. Uncontrolled hyperthyroidism may compromise perioperative hemodynamic stability and increase the risk of ischemic complications. In the largest surgical series to date, Li et al. described a cohort of 21 patients with coexisting MMD and GD, the majority of whom presented with neurologic symptoms during an active hyperthyroid phase.[31] All patients initiated endocrine therapy, and 17 underwent cerebral revascularization only after thyroid function had stabilized. Collectively, these observations support integrating endocrine control into operative planning as a perioperative risk-modifying strategy.

From a practical standpoint, early involvement of an endocrinologist should be considered in any patient with confirmed biochemical hyperthyroidism, suppressed TSH with elevated free T3/T4 levels, or clinical features suggestive of thyrotoxicosis. In addition, patients with fluctuating thyroid function, recurrent neurologic events, or planned surgical revascularization may benefit from co-management to ensure stable preoperative endocrine control. Establishing a multidisciplinary care pathway may improve both perioperative safety and long-term neurologic outcomes.

Across reported cases, antithyroid therapy was initiated at or shortly after neurologic presentation in the majority of patients. In nearly all cohorts, methimazole or propylthiouracil was employed as first-line treatment to regulate thyroid hormone levels.[4,31,36,46] In some series, beta-adrenergic blockade, most commonly propranolol or atenolol, was co-administered to mitigate tachycardia and hyperadrenergic symptoms associated with thyrotoxicosis.[19,46] Radioactive iodine (RAI) was used in several cohorts as a definitive treatment for GD,[2,14,31] often following initial stabilization with antithyroid medication. Surgical thyroidectomy was performed in select cases,[14,52] with careful endocrine and hemodynamic optimization prioritized to reduce perioperative instability. The available evidence indicates that sustained hormonal stability, rather than any particular treatment modality, is likely the primary determinant of neurologic risk. Restoration and maintenance of euthyroidism therefore remain central to management in this population.

The importance of judicious endocrine management is further underscored by reports of thyroid storm occurring during periods of medical or procedural stress, with subsequent neurologic deterioration in patients with concurrent GD and MMD. Thyroid storm represents the most severe manifestation of thyrotoxicosis, characterized by hypermetabolism, tachycardia, blood pressure instability, and multiorgan dysfunction. In patients with compromised cerebrovascular reserve, such physiologic stress may further impair cerebral perfusion and precipitate acute ischemic events. Several reports describe acute ischemic stroke occurring in the setting of documented thyroid storm.[10,38] In these cases, patients presented with severe thyrotoxicosis accompanied by pronounced tachycardia, metabolic derangement, and rapid neurologic decline. Additionally, Tendler et al. reported acute neurologic deficits developing shortly after RAI therapy in the setting of persistent Graves thyrotoxicosis, illustrating the potential for acute hormonal destabilization to precipitate cerebrovascular compromise.[51] Extreme sympathetic activation increases metabolic demand, and hemodynamic lability characteristic of thyroid crisis may overwhelm already impaired autoregulatory capacity in moyamoya vasculopathy. In the setting of fixed arterial stenosis and limited collateralization, even transient reductions in effective cerebral perfusion may be sufficient to precipitate infarction. These observations highlight the need for gradual endocrine correction, avoidance of abrupt medication withdrawal, and vigilant perioperative monitoring to minimize the risk of endocrine crisis.

### 7.2 Neurological and Surgical Management

Across reported cohorts, revascularization was typically deferred until active hyperthyroidism was corrected, reflecting concern about increased perioperative risk in the setting of uncontrolled systemic disease.[19,31,44,49] In the series described by Ryu et al., surgical intervention followed a defined period of medical optimization, with a mean interval of 142 days, stressing the deliberate sequence of care.[44] Emergent revascularization during overt thyrotoxicosis was rarely described, suggesting that stabilization was generally prioritized unless neurologic deterioration mandated urgent

intervention. The data indicate that surgical timing was intentionally aligned with systemic disease control, reflecting close coordination between endocrinology and neurosurgery to mitigate risk and refine surgical candidacy.

Both direct and indirect bypass techniques show favorable outcomes in patients with concurrent GD and MMD. Direct superficial temporal artery-middle cerebral artery (STA-MCA) bypass provides immediate augmentation of cerebral blood flow, whereas indirect techniques such as encephaloduroarteriosynangiosis (EDAS) and encephalomyosynangiosis (EMS) rely on gradual collateral formation.

Indirect revascularization techniques, most commonly EDAS, are the most frequently reported surgical strategy in patients with concurrent GD and MMD, particularly in pediatric cohorts.[5,29,31] These series describe favorable postoperative courses, with angiographic collateral formation and sustained neurologic stability during follow-up. Direct STA-MCA bypass, either alone or in combination with an indirect procedure, has been more commonly employed in adult patients with progressive ischemia.[7,19,44,49,52] Among these reports, surgery was performed after endocrine stabilization, and postoperative imaging confirmed bypass patency and improved cerebral perfusion. Overall, both direct and indirect approaches were associated with favorable functional outcomes. Current evidence does not demonstrate a clear superiority of one technique over the other in the context of GD; rather, operative strategy appears to follow established principles based on age and disease severity used in primary MMD.

Antiplatelet therapy was frequently employed as part of initial management in patients presenting with ischemic events. In the Ni et al. series, 11 of 12 patients received antiplatelet agents,[36] and Shah et al. similarly reported antiplatelet therapy in all patients.[46] Aspirin was the most commonly documented agent in individual case reports.[40,41,47] In select cases with recurrent symptoms or diagnostic uncertainty, short-term anticoagulation or combination therapy was used,[21,48] although treatment strategies were not standardized.

Beyond antithrombotic therapy, hemodynamic management was prioritized. Several reports describe neurologic deterioration during hyperventilation or thyrotoxic crisis, suggesting the potential vulnerability of collateral-dependent circulation to metabolic and hemodynamic stress.[16,27] These observations underscore the importance of maintaining hemodynamic stability in the acute setting. In this context, preservation of consistent cerebral perfusion is a central objective of early medical management in MMD associated with GD.

### 7.3 Emergency and Perioperative Considerations

Acute neurologic deterioration in GD-associated MMD has frequently been reported during periods of uncontrolled thyrotoxicosis or thyroid storm.[16,27,38] In several cases, worsening deficits or new infarctions occurred in temporal association with severe metabolic stress, including tachycardia, hypertension, hyperthermia, and, in one report, recurrent hyperventilation episodes preceding neurologic decline.[27] These observations suggest that collateral-dependent cerebral circulation may be particularly vulnerable during states of heightened sympathetic activity and metabolic demand.

Although direct hemodynamic measurements were not reported, the clinical patterns described across cases are consistent with impaired cerebrovascular reserve in the setting of distal internal carotid and proximal middle cerebral artery stenosis. Accordingly, careful maintenance of physiologic stability, including avoidance of hypotension, hypovolemia, and hypocapnia, is critical in the acute management of these patients.

Patients with concurrent GD and MMD present overlapping perioperative risks. The American Thyroid Association recommends achieving a euthyroid state prior to elective surgery to reduce the risk of thyroid storm, with medical optimization, including beta-adrenergic blockade, iodide, and glucocorticoids, when urgent intervention is required.[43] From a cerebrovascular standpoint, the American Heart Association/American Stroke Association recommends maintaining normotension (relative to baseline), normocapnia, and adequate intravascular volume during anesthesia to minimize ischemic risk in MMD.[13] Anesthetic guidance similarly emphasizes avoiding hypertension, hypocapnia, and dehydration, with consideration of preoperative hydration and invasive monitoring when appropriate.[13] These principles are particularly relevant in GD-associated MMD, as thyrotoxicosis increases metabolic demand and sympathetic tone, potentially exacerbating perfusion-metabolic mismatch in patients with impaired cerebrovascular reserve.[19] Consistent with this idea, reported case series deferred revascularization until thyroid function was adequately controlled prior to surgery.[44]

### 7.4 Clinical Decision-Making Algorithm for Concurrent MMD and GD Cases

Based on the synthesized clinical patterns, a pragmatic decision-making framework can be proposed to guide evaluation and management of patients presenting with suspected or confirmed MMD in the context of GD. This integrated workflow is summarized in Figure 1.

The algorithm outlines a dual-pathway approach integrating vascular and endocrine assessment. Vascular evaluation includes angiographic confirmation of MMD and assessment of superficial temporal artery (STA) caliber to guide selection of direct (STA–MCA) versus indirect (EDAS) revascularization. In parallel, thyroid function screening identifies hyperthyroidism, prompting endocrinology consultation and medical optimization to achieve euthyroid status prior to surgery. The framework emphasizes coordinated multidisciplinary management to reduce perioperative risk and optimize neurologic outcomes. Figure generated using AI-assisted tools (ChatGPT-5.2/DALL-E) and reviewed by the authors

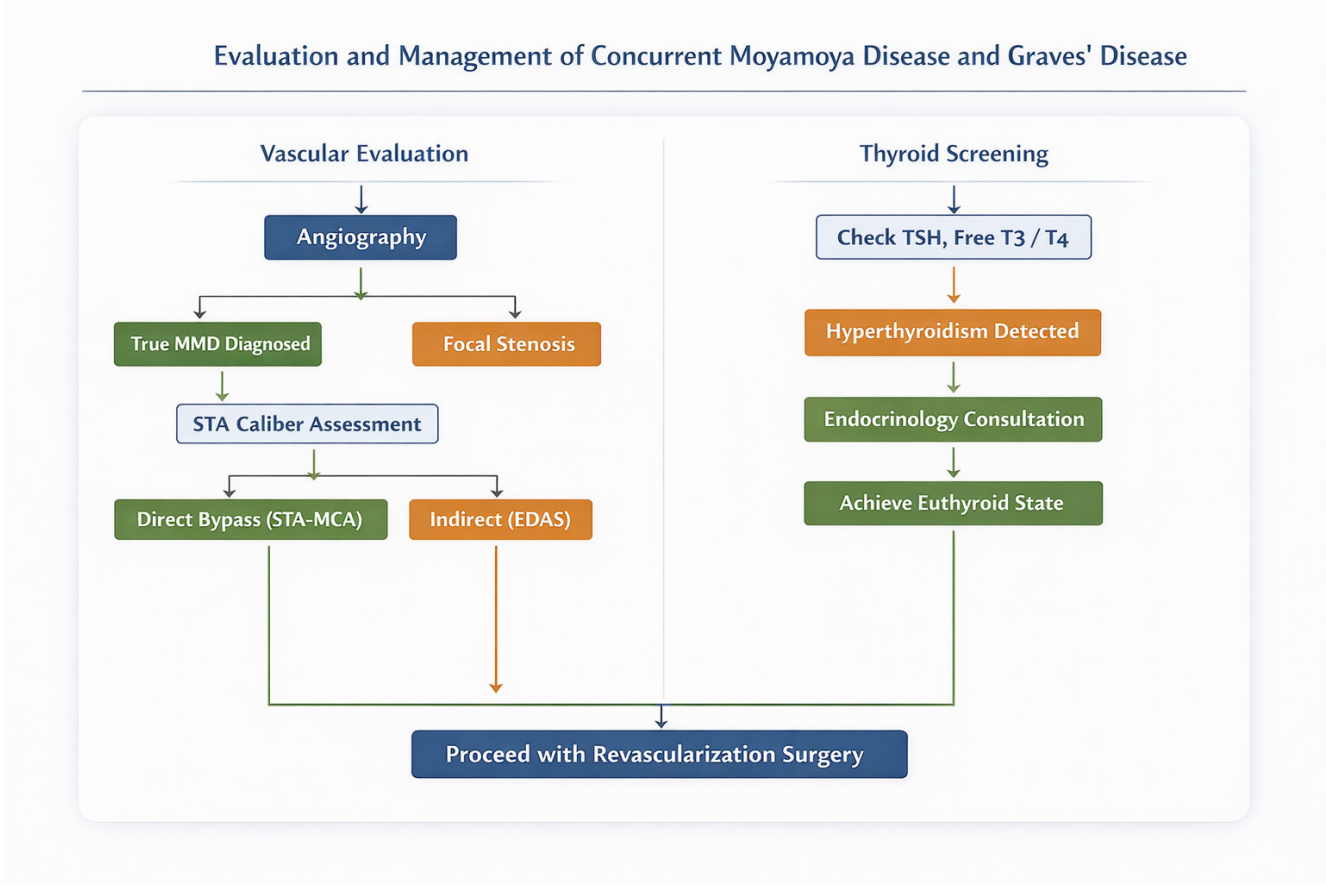


**FIGURE 1: Clinical decision-making algorithm for the evaluation and management of patients with concurrent MMD and GD.**

In symptomatic patients, initial evaluation should prioritize detailed vascular characterization through catheter-based angiography to distinguish true Moyamoya vasculopathy from focal or secondary intracranial stenosis. Following confirmation of MMD, assessment of donor vessel suitability, with particular attention to STA caliber, guides selection between direct bypass (STA–MCA) and indirect revascularization strategies such as EDAS.

In parallel, thyroid status should be systematically evaluated, particularly in patients presenting with ischemic events during physiologic stress or without a clear alternative etiology. Detection of hyperthyroidism should prompt early endocrinology consultation to guide medical optimization prior to surgical intervention. In patients with confirmed thyrotoxicosis, revascularization should generally be deferred until a euthyroid state is achieved, given the increased perioperative risk associated with metabolic instability and impaired cerebrovascular autoregulation.

This parallel, multidisciplinary approach integrates vascular, surgical, and endocrine decision-making, ensuring that both hemodynamic and systemic contributors to cerebral ischemia are addressed prior to intervention. From a practical standpoint, this framework is intended to guide real-world clinical decision-making by defining key inflection points for angiographic evaluation, surgical planning, and endocrine co-management.

### 7.5 Long-Term Outcomes

Recurrent cerebrovascular events were most frequently observed during periods of uncontrolled or relapsed hyperthyroidism. In the cohort described by Li et al., two patients developed new infarctions during the relapse of hyperthyroidism.[31] Both recovered and subsequently underwent additional revascularization procedures. The authors emphasized that surgical treatment improved cerebral perfusion and appeared to reduce further recurrence, while sustained thyroid control was considered essential in preventing additional events. Similar patterns were reported in cases involving medication non-adherence or thyroid storm, in which neurologic deterioration occurred during active thyrotoxicosis,[6,27] reinforcing the temporal association between metabolic instability and ischemic risk. Population-level observations by Hiruma et al. also demonstrated that new or progressive MMD manifestations often coincided with hyperthyroid states.[14]

In contrast, several surgical series reported no postoperative ischemic or hemorrhagic complications during the documented follow-up period. Im et al. and Suzuki et al. described favorable outcomes after revascularization.[19,49] Likewise, Ryu et al. reported no neurologic deterioration or surgical complications, with excellent functional outcomes (modified Rankin Scale $\leq 2$ in all patients) at 3 months postoperatively.[44] Notably, follow-up was heterogeneous and often limited to the early postoperative period, particularly in surgical series focused on perioperative endocrine management. While most authors described favorable short-

term neurologic outcomes after revascularization and thyroid stabilization, data on long-term outcomes remain limited.

A consistent finding throughout reports is the temporal relationship between thyroid dysfunction and neurologic events. Many ischemic presentations occurred during overt hyperthyroidism, and several studies noted clinical stabilization after normalization of thyroid hormone levels.[20,31] In the case described by Ishigami et al., neurologic improvement followed initiation of antithyroid therapy despite persistent angiographic abnormalities, suggesting that metabolic stabilization may influence cerebral hemodynamics even in the presence of fixed steno-occlusive disease.[20] Although a causal relationship between thyroid autoimmunity and the progression of MMD arteriopathy has not been established, the recurrent association between thyroid hormone fluctuations and cerebrovascular events highlights the importance of sustained endocrine management in long-term care. Collectively, these findings position thyroid control as a central, modifiable determinant of neurologic risk in a population.

## 8. Discussion

### 8.1 Synthesis of Findings Across Cases

Across cohort studies and case series, the coexistence of MMD and GD demonstrates reproducible clinical patterns. Although uncommon, this association is reproducible across studies. In a cohort of 320 adult MMD patients, 29 (9.1%) had GD.[2] In a larger surgical series of 1,493 MMD patients, 21 (1.4%) were diagnosed with coexisting GD.[31]

Ischemic presentation predominates in this subgroup. In the Li et al. series, 19 of 21 patients (90.4%) presented with cerebral infarction.[31] Similarly, Ni et al. reported ischemic stroke or transient ischemic attack in 11 of 12 patients (91.7%), with no hemorrhagic presentations.[36] These findings suggest a predominantly ischemic phenotype in patients with concurrent thyrotoxicosis.

A temporal relationship between hyperthyroidism and ischemic events is consistently reported. In the Ni et al. cohort, all patients with ischemic presentations were in a thyrotoxic state at the time of the event, and recurrent events were observed following withdrawal of anti-thyroid therapy.[36] Beyond acute presentation, GD appears associated with increased angiographic progression. During a mean follow-up of 106.4 ± 48.6 months, progression occurred in 40.0% of patients with GD compared with 20.7% without GD ($p = 0.036$), and stroke incidence was higher (48% vs 26.2%, $p = 0.027$).[2] GD remained an independent predictor of progression (OR 5.97, 95% CI 1.24–33.76, $p = 0.043$).

Together, these data support a consistent and biologically plausible association between thyrotoxicosis, ischemic presentation, and increased disease progression in patients with MMD, suggesting an underlying mechanistic linkage rather than coincidental coexistence. This review integrates endocrine physiology with cerebrovascular hemodynamics to provide a unified explanation for the temporal clustering of ischemic events observed across studies. This unified framework further supports the concept that GD may function as a disease-modifying factor in MMD through immune-mediated vascular injury and hemodynamic stress amplification.

### 8.2 Limitations of the Evidence

Although the association between GD and MMD has been consistently reported, the evidence remains limited by cohort size and study design. Ni et al. included 12 consecutive patients,[36] Li et al. reported 21 surgical cases,[31] and Chen et al. identified 29 patients with GD within a cohort of 320 adult MMD patients.[2] Even in the largest study, the subgroup with concurrent GD remained relatively small, limiting precision of risk estimates and widening confidence intervals, as reflected by the broad 95% CI (1.24–33.76) for progression risk reported by Chen et al..[2]

Radiographic characterization is also not uniform. In Ni et al., 50% of patients demonstrated either asymmetric or unilateral vessel involvement, which differs from the classic symmetric bilateral pattern described in primary MMD.[36] However, not all studies reported Suzuki stage or standardized progression metrics, making it difficult to determine whether this subgroup represents a distinct angiographic phenotype.

Although thyroid autoantibodies were elevated in all 12 patients in Ni et al., no study has longitudinally correlated antibody titers with angiographic change or stroke recurrence.[36] Without serial immunologic data, it remains unclear whether immune activity contributes directly to structural vascular progression or primarily modifies hemodynamic stress.

Furthermore, heterogeneity in reporting and lack of standardized thyroid status definitions further limit comparability across studies.

### 8.3 Implications for Clinical Practice

Beyond overall stroke risk, several phenotype-specific features may influence clinical management. In Ni et al., 9 of 12 patients demonstrated bilateral terminal internal carotid stenosis, while 3 had unilateral disease, and 2 patients had posterior cerebral artery involvement.[36] These findings suggest that vascular involvement may extend beyond the anterior circulation in this subgroup and support comprehensive vascular imaging at diagnosis.

Watershed infarcts were common in the Ni et al. cohort, occurring in 8 of 12 patients, which may reflect impaired cerebral autoregulation during hyperthyroid states.[36] Thyrotoxicosis is known to increase cerebral blood flow and metabolic demand, and acute hormonal fluctuations may destabilize borderline perfusion territories. Clinically, this supports careful hemodynamic monitoring and avoidance of abrupt thyroid hormone changes.

In the surgical cohort reported by Li et al.,[31] revascularization following endocrine stabilization resulted in neurological improvement in the majority of patients, and no perioperative thyroid storm was reported. Although comparative

perioperative data are lacking, these observations suggest that preoperative endocrine optimization may reduce metabolic stress during revascularization.

If future studies confirm a higher prevalence of GD in specific populations or clinical subgroups of MMD patients, this may justify a structured co-management model involving routine endocrine evaluation, similar to multidisciplinary care pathways established for pituitary disorders. Such an approach could facilitate earlier detection of thyrotoxicosis, reduce perioperative risk, and optimize long-term disease control.

### 8.4 Future Directions

Future studies should aim to clarify whether the vascular asymmetry observed in 50% of patients in Ni et al. represents a distinct MMD subtype associated with autoimmune thyroid disease.[36] Longitudinal imaging studies incorporating standardized Suzuki staging could determine whether unilateral or asymmetric lesions progress differently in patients with GD.

Prospective studies incorporating serial thyroid hormone levels and antibody titers may help define whether biochemical severity correlates with angiographic progression or infarct pattern. Additionally, advanced imaging modalities assessing cerebral perfusion and cerebrovascular reactivity could clarify whether hyperthyroidism primarily affects vascular structure or autoregulatory capacity.

Given the relatively low prevalence of coexisting GD in large MMD cohorts (1.4–9.1%),[2,31] multicenter collaboration will be necessary to generate adequately powered studies capable of refining risk stratification and management strategies.

## 9. Conclusion

The coexistence of MMD and GD, although uncommon, demonstrates reproducible clinical patterns across reported cohorts and case series. Most patients present with ischemic cerebrovascular events, and neurologic symptoms frequently occur during periods of active thyrotoxicosis.[31,36,46] These observations suggest that thyroid dysfunction contributes to clinical instability in patients with compromised cerebrovascular reserve.

Proposed mechanisms include autoimmune activity, endothelial dysfunction, and the hemodynamic stress associated with hyperthyroidism, which may exacerbate perfusion vulnerability in stenotic intracranial vessels.[2,36] Clinically, reported cases consistently emphasize the importance of stabilizing thyroid function before surgical revascularization and maintaining careful endocrine control to reduce the risk of recurrent neurologic events.[31]

The development of a structured clinical decision-making framework integrating vascular imaging, endocrine evaluation, and surgical planning may enhance the management of patients with concurrent MMD and GD and improve both neurologic and systemic outcomes.

Although current evidence is limited by small cohorts and observational designs, the coexistence of MMD and GD represents a clinically significant and mechanistically linked interaction, in which thyrotoxicosis acts as a modifiable trigger of ischemic events in patients with impaired cerebrovascular reserve. Coordinated endocrine and neurovascular management, with emphasis on sustained euthyroidism, is essential to reducing neurologic risk.

## REFERENCES


1. Burgos-Sanchez C, Bataba E, Costello J, Bess D, Dedekam E. A thyroid storm causing strokes and unmasking moyamoya. Radiol Case Rep 2025;20(7):3388–92. doi: 10.1016/j.radcr.2025.03.050.
2. Chen J-B, Lei D, He M, et al. Clinical features and disease progression in moyamoya disease patients with Graves disease. J Neurosurg 2015;123(4):848–55. doi: 10.3171/2015.8.JNS141140a.
3. Chen JB, Liu Y, Zhou LX, et al. Increased prevalence of autoimmune disease in patients with unilateral compared with bilateral moyamoya disease. J Neurosurg 2016;124(5):1215–20. doi: 10.3171/2015.4.JNS142936.
4. Chen JB, Liu Y, Zhou LX, et al. Prevalence of autoimmune disease in moyamoya disease patients in Western Chinese population. J Neurol Sci 2015;351(1–2):184–6. doi: 10.1016/j.jns.2015.02.037.
5. Cheon CK, Kim SY, Yoo JH. Two adolescent patients with coexistent Graves' disease and Moyamoya disease in Korea. Korean J Pediatr 2014;57(6):287–91. doi: 10.3345/kjp.2014.57.6.287.
6. Choi J, Suthakar P, Farmand F. Fatal outcome in a Hispanic woman with moyamoya syndrome and Graves' disease. Endocrinol Diabetes Metab Case Rep 2016;2016:16–0045. doi: 10.1530/EDM-16-0045.
7. Endo H, Fujimura M, Niizuma K, et al. Efficacy of revascularization surgery for moyamoya syndrome associated with Graves' disease. Neurol Med Chir (Tokyo) 2010;50(11):977–83. doi: 10.2176/nmc.50.977.
8. Gao-Rui C, Guo-Neng C, Wen-Xue J. Aneurysmal bone cyst of the proximal femur concomitant with Graves' disease and Moyamoya disease: report of a rare case. J Int Med Res 2022;50(5):3000605221097669. doi: 10.1177/03000605221097669.
9. Garcin B, Louissaint T, Hosseini H, et al. Reversible chorea in association with Graves' disease and moyamoya syndrome. Mov Disord 2008;23(4):620–2. doi: 10.1002/mds.21941.
10. Gill JH, Nam TK, Jung HK, et al. Acute cerebral infarction combined with a thyroid storm in a patient with both Moyamoya syndrome and Graves' disease. J Cerebrovasc Endovasc Neurosurg 2022;24(2):160–5. doi: 10.7461/jcen.2021.E2021.07.003.
11. Golomb MR, Biller J, Smith JL, et al. A 10-year-old girl with coexistent moyamoya disease and Graves' disease. J Child Neurol 2005;20(7):620–4. doi: 10.1177/08830738050200071801.
12. Gon Y, Sakaguchi M, Oyama N, et al. Diagnostic Utility of Contrast-enhanced 3D T1-weighted Imaging in Acute Cerebral Infarction Associated with Graves Disease. J Stroke Cerebrovasc Dis 2017;26(2):e38–40. doi: 10.1016/j.jstrokecerebrovasdis.2016.11.005.
13. Gonzalez NR, Amin-Hanjani S, Bang OY, et al. Adult Moyamoya Disease and Syndrome: Current Perspectives and Future Directions: A Scientific Statement From the American Heart Association/American Stroke Association. Stroke 2023;54(10):e465–79. doi: 10.1161/STR.0000000000000443.
14. Hiruma M, Watanabe N, Mitsumatsu T, et al. Clinical features of moyamoya disease with Graves' disease: a retrospective study of 394,422 patients with thyroid disease. Endocr J 2023;70(2):141–8. doi: 10.1507/endocrj.EJ22-0319.
15. Hoang TD, Stocker DJ, Chou EL, Burch HB. 2022 Update on Clinical Management of Graves Disease and Thyroid Eye Disease.

Endocrinol Metab Clin North Am 2022;51(2):287–304. doi: 10.1016/j.ecl.2021.12.004.

16. Hsu SW, Chaloupka JC, Fattal D. Rapidly progressive fatal bihemispheric infarction secondary to Moyamoya syndrome in association with Graves thyrotoxicosis. AJNR Am J Neuroradiol 2006;27(3):643–7.
17. Huang M, Tang S, Zou Y, et al. Ischemic Stroke and Intraventricular Hemorrhage in Moyamoya Syndrome Associated With Graves' Disease: A Case Report. Neurologist 2023;28(1):42–5. doi: 10.1097/NRL.0000000000000428.
18. Ihara M, Yamamoto Y, Hattori Y, et al. Moyamoya disease: diagnosis and interventions. Lancet Neurol 2022;21(8):747–58. doi: 10.1016/S1474-4422(22)00165-X.
19. Im SH, Oh CW, Kwon OK, Kim JE, Han DH: Moyamoya disease associated with Graves disease: special considerations regarding clinical significance and management. J Neurosurg 102:1013-1017, 2005. doi: 10.3171/jns.2005.102.6.1013.
20. Ishigami A, Toyoda K, Suzuki R, et al. Neurologic improvement without angiographic improvement after antithyroid therapy in a patient with Moyamoya syndrome. J Stroke Cerebrovasc Dis 2014;23(5):1256–8. doi: 10.1016/j.jstrokecerebrovasdis.2013.08.025.
21. Ito H, Yokoi S, Yokoyama K, et al. Progressive stenosis and radiological findings of vasculitis over the entire internal carotid artery in moyamoya vasculopathy associated with graves' disease: a case report and review of the literature. BMC Neurol 2019;19(1):34. doi: 10.1186/s12883-019-1262-1.
22. Ito K, Hara S, Inaji M, et al. Routine screening serum tests to detect underlying thyroid and autoimmune diseases in patients with moyamoya disease. Clin Neurol Neurosurg 2024;243:108403. doi: 10.1016/j.clineuro.2024.108403.
23. Jea A, Smith ER, Robertson R, et al. Moyamoya syndrome associated with Down syndrome: outcome after surgical revascularization. Pediatrics 2005;116(5):e694-701. doi: 10.1542/peds.2005-0568.
24. Jehangir W, Singh Z, Bhatt H, et al. A New Early Finding of Moyamoya-Like Phenomena. J Clin Med Res 2015;7(8):643–5. doi: 10.14740/jocmr2193w.
25. Kamasaki H, Takeuchi T, Mikami T, et al. A Case of Graves' Disease Diagnosed in the Course of Bilateral Carotid Artery Stenoses (Moyamoya Disease); A Case Report and Review of the Literature. Clin Pediatr Endocrinol 2013;22(3):39–44. doi: 10.1292/cpe.22.39.
26. Kim JY, Kim BS, Kang JH. Dilated cardiomyopathy in thyrotoxicosis and Moyamoya disease. Int J Cardiol 2001;80(1):101–3. doi: 10.1016/s0167-5273(01)00475-2.
27. Ku BD, Park KC, Yoon SS. Fatal ischemic stroke in a case of progressive moyamoya vasculopathy associated with uncontrolled thyrotoxicosis. Korean J Intern Med 2015;30(4):543–6. doi: 10.3904/kjim.2015.30.4.543.
28. Kushima K, Satoh Y, Ban Y, et al. Graves' thyrotoxicosis and Moyamoya disease. Can J Neurol Sci 1991;18(2):140–2. doi: 10.1017/s0317167100031607.
29. Lee R, Sung K, Park YM, et al. A case of Moyamoya disease in a girl with thyrotoxicosis. Yonsei Med J 2009;50(4):594–8. doi: 10.3349/ymj.2009.50.4.594.
30. Leno C, Mateo I, Cid C, et al. Autoimmunity in Down's syndrome: another possible mechanism of Moyamoya disease. Stroke 1998;29(4):868–9. doi: 10.1161/01.str.29.4.868.
31. Li D, Yang W, Xian P, et al. Coexistence of moyamoya and Graves' diseases: the clinical characteristics and treatment effects of 21 Chinese patients. Clin Neurol Neurosurg 2013;115(9):1647–52. doi: 10.1016/j.clineuro.2013.02.018.
32. Maezawa Y, Nagasaki K, Aiyama H, et al. Moyamoya Syndrome: Differential Diagnosis in Patients With Central Nervous System Symptoms and Hyperthyroidism. Cureus 2024;16(2):e53519. doi: 10.7759/cureus.53519.
33. Malik S, Russman AN, Katramados AM, et al. Moyamoya syndrome associated with Graves' disease: a case report and review of the literature. J Stroke Cerebrovasc Dis 2011;20(6):528–36. doi: 10.1016/j.jstrokecerebrovasdis.2010.03.006.
34. Nakamura H, Sato K, Yoshimura S, et al. Moyamoya Disease Associated with Graves' Disease and Down Syndrome: A Case Report and Literature Review. J Stroke Cerebrovasc Dis 2021;30(1):105414. doi: 10.1016/j.jstrokecerebrovasdis.2020.105414.
35. Neves N, Coelho S, Marto N, et al. Moyamoya Disease and Syndrome in Caucasian Patients. Cureus 2023;15(4):e37768. doi: 10.7759/cureus.37768.
36. Ni J, Zhou LX, Wei YP, et al. Moyamoya syndrome associated with Graves' disease: a case series study. Ann Transl Med 2014;2(8):77. doi: 10.3978/j.issn.2305-5839.2014.08.03.
37. Nóbrega PR, da Costa FBS, Rodrigues PGB, et al. Moyamoya associated with Turner syndrome in a patient with type 2 spinocerebellar ataxia-Occam's razor or Hickam's dictum: a case report. BMC Neurol 2022;22(1):381. doi: 10.1186/s12883-022-02912-x.
38. Noh BH, Cho S-W, Ahn SY. Simultaneous occurrence of diabetic ketoacidosis, thyroid storm, and multiple cerebral infarctions due to Moyamoya disease. J Pediatr Endocrinol Metab 2016;29(2):221–5. doi: 10.1515/jpem-2015-0204.
39. Ohba S, Nakagawa T, Murakami H. Concurrent Graves' disease and intracranial arterial stenosis/occlusion: special considerations regarding the state of thyroid function, etiology, and treatment. Neurosurg Rev 2011;34(3):297–304; discussion 304. doi: 10.1007/s10143-011-0311-z.
40. Pierman G, Vandermeeren Y, Jonas C, et al. Association of Graves' disease and Moyamoya syndrome in a Caucasian woman from Western Europe: vascular effects of anti-TSH receptor antibodies? Endocrinology, Diabetes & Metabolism Case Reports 2024; 2024(2), Article 23-0138, 23-0138. doi.org/10.1530/EDM-23-0138.
41. Ramírez-Quiñones J, Wahlster S, Barrientos-Imán D, et al. Bilateral Ischemic Strokes Secondary to Moyamoya Syndrome Associated With Graves Thyrotoxicosis in a Patient of Amerindian Descent From Peru: A Case Report. Cureus 2022;14(7):e26546. doi: 10.7759/cureus.26546.
42. Ren SC, Gao BQ, Yang WL, et al. Von Willebrand factor and coagulation factor VIII in Moyamoya disease associated with Graves' disease: A case report. Exp Ther Med 2016;12(5):3195–200. doi: 10.3892/etm.2016.3769.
43. Ross DS, Burch HB, Cooper DS, et al. 2016 American Thyroid Association Guidelines for Diagnosis and Management of Hyperthyroidism and Other Causes of Thyrotoxicosis. Thyroid 2016;26(10):1343–421. doi: 10.1089/thy.2016.0229.correx.
44. Ryu B, Kawamata T, Yamaguchi K, et al. Moyamoya disease concurrent with Graves' disease treated by direct bypass: clinical features and treatment strategies. Acta Neurochir (Wien) 2015;157(7):1095–102. doi: 10.1007/s00701-015-2422-8.
45. Sasaki T, Nogawa S, Amano T. Co-morbidity of moyamoya disease with Graves' disease. report of three cases and a review of the literature. Intern Med 2006;45(9):649–53. doi: 10.2169/internalmedicine.45.1543.
46. Shah NH, Khandelwal P, Gordon-Perue G, et al. Acute Thyrotoxicosis of Graves Disease Associated with Moyamoya Vasculopathy and Stroke in Latin American Women: A Case Series and Review of the Literature. World Neurosurg 2016;92:95–107. doi: 10.1016/j.wneu.2016.04.122.
47. Shen AL, Ryu SJ, Lin SK. Concurrent moyamoya disease and Graves' thyrotoxicosis: case report and literature review. Acta Neurol Taiwan 2006;15(2):114–9.
48. Shimogawa T, Morioka T, Sayama T, et al. Champagne bottle neck sign in a patient with Moyamoya syndrome. World J Clin Cases 2014;2(9):474–7. doi: 10.12998/wjcc.v2.i9.474.
49. Suzuki S, Mitsuyama T, Horiba A, et al. Moyamoya disease complicated by Graves' disease and type 2 diabetes mellitus: report of two cases. Clin Neurol Neurosurg 2011;113(4):325–9. doi: 10.1016/j.clineuro.2010.11.022.
50. Tashiro R, Niizuma K, Khor SS, et al. Identification of HLA-DRB1*04:10 allele as risk allele for Japanese moyamoya disease and its association with autoimmune thyroid disease: A case-control study. PLoS One 2019;14(8):e0220858. doi: 10.1371/journal.pone.0220858.
51. Tendler BE, Shoukri K, Malchoff C, et al. Concurrence of Graves' Disease and Dysplastic Cerebral Blood Vessels of the Moyamoya

Variety. Thyroid 1997;7(4):625–9.

52. Tokimura H, Tajitsu K, Takashima H, et al. Familial moyamoya disease associated with Graves' disease in a mother and daughter. Two case reports. Neurol Med Chir (Tokyo) 2010;50:668-674.

53. Utku U, Asil T, Celik Y, et al. Reversible MR angiographic findings in a patient with autoimmune Graves disease. AJNR Am J Neuroradiol 2004;25(9):1541–3.

54. Wang WS, Wu SL, Chan WC, et al. Case report: Steroid-responsive acute chorea as first presentation of the coexistence of Moyamoya and Graves' disease. Front Neurol 2023;14:1170837. doi: 10.3389/fneur.2023.1170837.

55. Wunderle KB, McCulley C. Smoke and Mirrors: Moyamoya Syndrome. Am J Med 2017;130(9):1045–8. doi: 10.1016/j.amjmed.2017.05.008.

56. Xuan YY, Li TF, Zhang L, et al. ANCA positive relapsing polychondritis, Graves disease, and suspected moyamoya disease: A case report. Medicine (Baltimore) 2017;96(51):e9378. doi: 10.1097/MD.0000000000009378.

57. Zhang Q, Liu Y, Yu L, et al. The Association of the RNF213 p.R4810K Polymorphism with Quasi-Moyamoya Disease and a Review of the Pertinent Literature. World Neurosurg 2017;99:701-708.e1. doi: 10.1016/j.wneu.2016.12.119.