JVIN Journal of Vascular and Interventional Neurology

OFFICIAL JOURNAL OF ZEENAT QURESHI STROKE INSTITUTE

A Rare Case of Vertebral Artery Dissection in Both Limbs of Fenestration

Kojiro Ishikawa, MD[1,*], Takeshi Kinkori, MD[1], Naoto Kawaguchi, MD[1], Takashi Sakuma, MD[1], Keita Suzuki, MD[1], Yusuke Sato MD[1], Kenichi Watanabe, PhD[2]

[1] *Department of Neurosurgery, Okazaki city hospital, Okazaki, Aichi, Japan*

[2] *Department of Radiology, Okazaki city hospital, Okazaki, Aichi, Japan*

Abstract

We present a rare case of dissection of both limbs of a vertebral artery fenestration, with a ruptured dissecting aneurysm in one limb. A 54-year-old man was diagnosed subarachnoid hemorrhage. An emergency digital subtraction angiography revealed a fenestration in the intracranial region of the left vertebral artery. The limb of the ventral side showed a fusiform dilation in the proximal and the limb of the dorsal side showed irregular stenosis. These were characteristic of arterial dissection. We diagnosed dissection of both limbs of the vertebral artery fenestration, and a ruptured dissecting aneurysm of the ventral limb. Endovascular trapping of the ventral limb was performed. A follow-up image showed that the stenosis of the dorsal limb had completely resolved to normal, suggesting spontaneous remodeling of the dissection. The vascular fragility inherent in the fenestration may have contributed to the dissection, suggesting dissections occurring simultaneously in both limbs of the fenestration.

Keywords— Fenestration, Vertebral artery, Dissection, Ruptured dissecting aneurysm.

Abbreviations— VA: vertebral artery, CT: computed tomography, SAH: subarachnoid hemorrhage, DSA: digital subtraction angiography, 3D-RA: 3-dimensional rotational angiography, ASA: anterior spinal artery, PICA: posterior inferior cerebellar artery, MRA: magnetic resonance angiography.

INTRODUCTION

Vertebral artery (VA) fenestrations are relatively rare.[1] Although fenestrations have been associated with saccular cerebral aneurysms, dissecting aneurysms have rarely been associated with fenestrations.[2] Additionally, to our knowledge, there have been no reports of arterial dissection of both limbs of a fenestration. In this report, we present a rare case of dissection of both limbs of a VA fenestration, with a ruptured dissecting aneurysm in one limb.

CASE REPORT

A 54-year-old man had a sudden onset of severe headache, and computed tomography (CT) showed subarachnoid hemorrhage (SAH) predominantly in the posterior fossa (Figure 1a). The patient's medical history included hypertension and hyperlipidemia, both under medical control. He had no family history of neurological disease. On admission, he was slightly drowsy and presented with a conjugate eye deviation to the left.

An emergency digital subtraction angiography (DSA) and 3-dimensional rotational angiography (3D-RA) revealed a fenestration in the intracranial region of the left VA (Figure 1b). Two limbs merged on the anterolateral side of the pons to form a single left VA. The limb of the ventral side showed a fusiform dilation in the proximal and anterior spinal artery (ASA), originating from the distal portion of the dilation. On the other hand, the limb of the dorsal side showed a bifurcated posterior inferior cerebellar artery (PICA), and irregular stenosis distal to it. These were characteristic of arterial dissection. We diagnosed dissection of both limbs of the VA fenestration, and a ruptured dissecting aneurysm of the ventral limb. Endovascular trapping of the ventral limb was performed at the shortest length possible. Finally, the ventral limb was successfully occluded, and blood flow in the dorsal limb was preserved (Figure 2a). DSA of the right VA helped visualize the left ASA, and confirmed retrograde flow to the left VA (Figure 2b). There were no perioperative complications and no additional deterioration in the patient's neurological condition during the vasospasm period.

Magnetic resonance angiography (MRA) 2 weeks after symptom onset showed the intimal flap of the dorsal limb, which is characteristic of arterial dissection (Figure 3a). Three weeks after onset, DSA revealed complete occlusion

Vol.14, No. 1, pp. 9-11, Published March, 2023.

All Rights Reserved by JVIN. Unauthorized reproduction of this article is prohibited.

*Corresponding Author: Kojiro Ishikawa, MD, Department of Neurosurgery, Okazaki city hospital, Okazaki, Aichi, Japan 3-1 Gosyago, Koryuji-cho, Okazaki-city, Aichi 444-8553, Japan, Tel: +81-564218111, Fax; +81-564252913, E-mail address:ishikou1031@hotmail.co.jp.

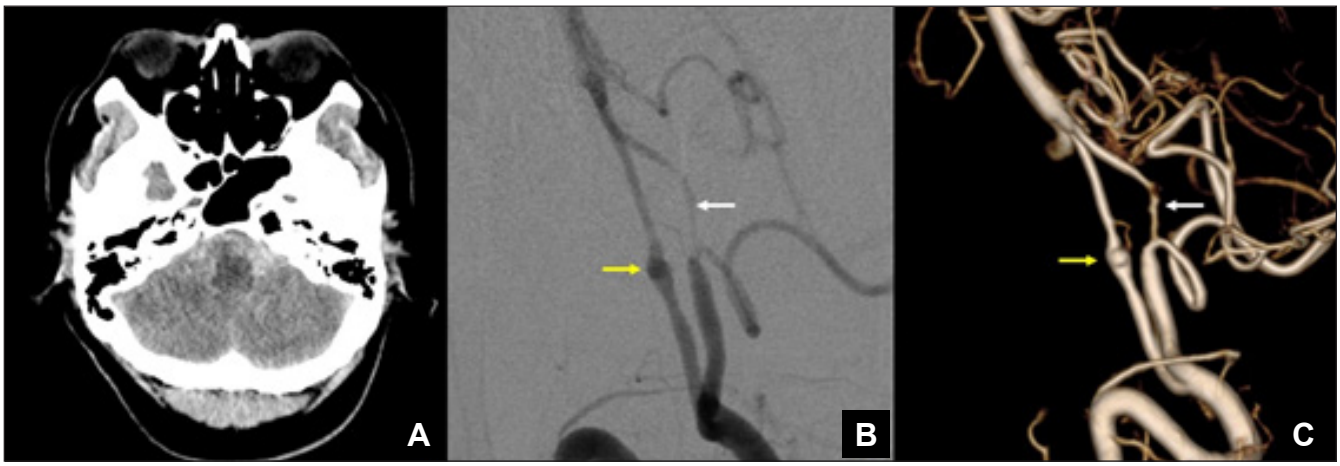

FIGURE 1: (A) Computed tomography (CT) at admission showed subarachnoid hemorrhage (SAH) predominantly in the posterior fossa. (B) Imaging findings in the emergency digital subtraction angiography (DSA) and 3-dimensional rotational angiography (3D-RA) at lateral view. Left vertebral angiography revealed the fenestration. The limb of the ventral side showing a fusiform dilation (yellow arrow) in the proximal and the anterior spinal artery (ASA) originated from the distal portion of the dilation. The limb of the dorsal side showing a bifurcated posterior inferior cerebellar artery (PICA) and irregular stenosis (white arrow) distal to it. Two limbs merged on the anterolateral side of the pons to form a single left vertebral artery (VA).

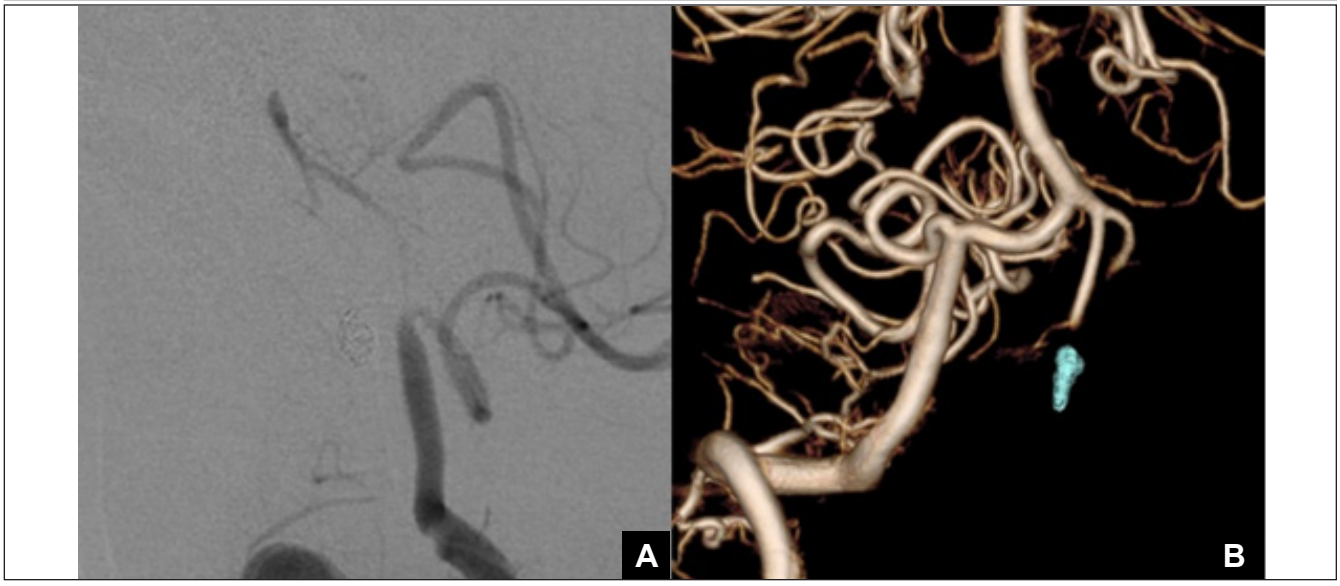

FIGURE 2: Imaging findings during and after endovascular trapping for the ventral limb. (A) Left vertebral angiography showing no blood flow by the coil mass and successfully occlusion in the ventral limb. Blood flow in the dorsal limb and basilar artery was preserved. (B) Right vertebral 3-dimensional rotational angiography (3D-RA) at frontal view showing the retrograde flow to the left VA and the visualization of the left ASA.

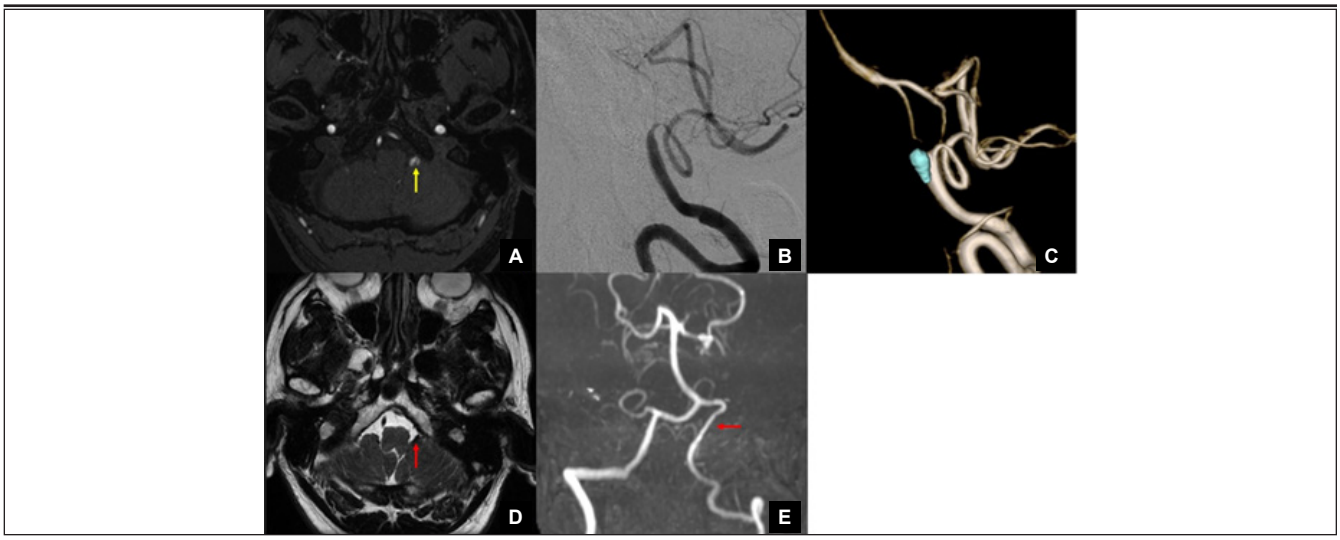

FIGURE 3: (A) Magnetic resonance angiography (MRA) two weeks after the onset showing intimal flap of the dorsal limb (yellow arrow). (B) Digital subtraction angiography (DSA) three weeks after the onset showing complete occlusion of the ventral limb. (C) 3-dimensional rotational angiography (3D-RA) showing the mild progressive stenosis of the dorsal limb and the improving irregularity in the vessel wall. Follow up Cube image (D) and MIP image (E) in MRI at two months after onset revealed that the stenosis of the dorsal limb had completely resolved to a normal and the blood flow was well (red arrow).

of the ventral limb and mild progressive stenosis of the dorsal limb, but the irregularity in the vessel wall had improved. Thus, morphological changes may be attributed to the arterial dissection (Figure 3b).

The patient was discharged from the hospital with mild diplopia.

A follow-up 6 months after onset showed that the stenosis of the dorsal limb had completely resolved to normal, suggesting spontaneous remodeling of the dissection (Figure 3c; 3d).

DISCUSSION

The frequency of intracranial VA fenestration has been reported to 0.4–2.0%.[3] Some studies have reported an association between intracranial fenestration and increased risk of saccular aneurysm formation; defects in the tunica media of the vessel and local hemodynamic forces at the bifurcation may precipitate this formation.[4] On the other hands, little is known about associations between dissecting aneurysms and VA fenestrations. It is generally considered that intracranial VA dissection is spontaneous and intrinsic, such as Ehlers–Danlos syndrome type 4 or Marfan's syndrome, vascular fragility caused by arteriosclerosis.[5] To our knowledge, only seven patients with dissection of one limb of a VA fenestration have been reported in the literature.[6,7] It was reported to be unlikely that atherosclerosis was the main cause of dissection in the aforementioned seven patients because they were young, and because vascular fragility inherent in the fenestration may have contributed to the dissection. Our patient had a history of hypertension and hyperlipidemia, but these were well controlled with medication; angiography also showed no atherosclerotic changes, suggesting that vascular fragility of the fenestration caused the dissection.

VA dissection usually occurs unilaterally, but bilateral dissection is not uncommon. Several studies have reported that approximately 8–43% of VA dissections are bilateral.[8] These reports suggested that patients with VA dissections had bilateral arterial vulnerability. This is similar to our patient, who had dissections occurring simultaneously in both limbs of the fenestration due to the vascular fragility of the fenestration. In this case, the dissecting aneurysm was treated with endovascular trapping of the ventral limb; however, the treatment strategy must be carefully considered, depending on the structural integrity of each limb and the presence of normal arterial branches (i.e., the involvement of PICA, perforation of the brain stem, and the development status of contralateral VA).

CONCLUSION

We present a rare case of dissection of both limbs of a VA fenestration, with a ruptured dissecting aneurysm in one limb. When we encounter dissection of VA fenestrations, we should presume the presence of the abnormality in both limbs, and plan a treatment strategy while considering hemodynamics and perforations.

DECLARATIONS

Funding

None

Ethical Approval

Our institution does not require ethical approval for reporting individual case.

This paper obtained consent from the patient to use his medical information in this case report.

Conflict of Interest

The authors declare that the research was conducted in the absence of any commercial or financial relationships that could be construed as a potential conflict of interest.

Consent for publication

Not applicable.

Authors' contributions

All authors listed have made a substantial, direct and intellectual contribution to the work, and approved it for publication.

Acknowledgments

None

REFERENCES

1. Sanders WP, Sorek PA, Mehta BA. Fenestration of intracranial arteries with special attention to associated aneurysms and other anomalies. Am J Neuroradiol 1993;14: 675-680.
2. Ikeda H, Sano N, Torikoshi S, et al. Dissection of the vertebral artery fenestration limb presenting with occlusion after rupture. World Neurosurgery 2020;135: 324-329.
3. Uchino A, Saito N, Okada Y, et al. Fenestrations of the intracranial vertebrobasilar system diagnosed by MR angiography. Neuroradiology 2012;54(5): 445-50.
4. Mira A Patel, Justin M Caplan, Wuyang Yang, et al. Arterial fenestrations and their association with cerebral aneurysms. J Clin Neurosci 2014;21(12): 2184-8. 2014
5. Y-K Kim, Sam S. Cervical artery dissection: pathology, epidemiology and management. Thromb Res 2009;123(6): 810-21.
6. David N, Cheemun L, Christine DM. Dissection of a limb of a vertebral artery fenestration: Case report. Can J Neurol Sci 2016;43(2): 329-31.
7. Ro A, Kageyama N, Abe N, et al. Intracranial vertebral artery dissection resulting in fatal subarachnoid hemorrhage: clinical and histopathological investigations from a medicolegal perspective. J Neurosurg 2009;110(5): 948-54.
8. W Y Zhao, T Krings, H Alvarez, et al. Spontaneous mirror dissections of cervicocephalic arteries. Pathomechanical considerations. Interventional Neuroradiology 2006;12(1): 73-8.