JVIN | Journal of Vascular and Interventional Neurology

OFFICIAL JOURNAL OF ZEENAT QURESHI STROKE INSTITUTE

Preclinical First Report of Optical Coherence Tomography (OCT) to Evaluate Extracranial Vertebral Artery Dissection Caused by Drug-Coated Balloon Angioplasty

Zhongjun Chen[1], Tieping Fan[1], Xusheng Zhao[1], Di Li[1], Teng Hu[1], Adnan I. Qureshi[2,*].

[1] Department of Neurointervention, Dalian Municipal Central Hospital affiliated with Dalian Medical University, Dalian, China, 826 Xinan Road, Dalian 116033, China.

[2] Department of Neurology , University of Missouri - Columbia, CS & E Building, 5 Hospital Drive, CE507, Columbia, MO 65212

Abstract

Background— Optical Coherence Tomography (OCT) in a new technology with potential neurointerventional applications. We report the use of OCT to detect intraluminal dissection secondary to angioplasty in the extracranial vertebral artery.

Methods— OCT were acquired using Dragonfly imaging catheter (Dragonfly Duo;LightLab Imaging, Inc.,St. Jude Medical.) and data were analyzed by the ILUMIEN OPTIS Imaging System (Abbott Medical,Westfort,USA) in cervical vertebral artery in an adult patient presented with a 7-day history of dizziness, vertigo and right limb weakness associated with a long stenotic segment of the proximal right vertebral artery segment.

Results— Angiogram showed good patency and no proximal dissection after drug eluting balloon dilation of the stenosis. However, OCT showed two distinct dissections and a 3.5*35 mm RQES drug eluting stent was placed. OCT showed resolution of dissection and new high signals distributed unevenly on the initial surface, presumably drug particles released from the drug eluting balloon.

Conclusion— The first reported case suggests that OCT is feasible for imaging proximal vertebral artery lesion and may be more sensitive than angiogram in detecting post angioplasty vertebral artery dissection.

Keywords— optical coherence tomography; vertebral artery; dissection; angiography; angioplasty.

INTRODUCTION

An adult patient presented with a 7-day history of dizziness, vertigo and right limb weakness. The patient had a 20-year history of poorly controlled essential hypertension. On examination, the patient was noticed to ataxic gait, right limb weakness, speech disorder, limb ataxia and dystonia. These symptoms did not improve after initiation of antiplatelet and intensive lipid-lowering drug treatment. Cerebral angiogram demonstrated a long stenotic segment of the proximal right vertebral artery segment (Figures 1A). Optical Coherence Tomography(OCT) was used to acquire endovascular images. Methods and euipments:Dragonfly imaging catheter (Dragonfly Duo; LightLab Imaging, Inc.,St.Jude Medical.) was irrigated with 3ml contrast agent and connected with the DOC connector of the system, rotated clockwise 1/8 times to connection, calibrated automatically. The imaging catheter was passed through the distal end of the stenosis through the guide wire, and the second mark of the catheter passed through the lesion more than 10mm. 15ml contrast agent was pushed through the guiding catheter (speed: 10ml/s) to clear the blood. The system automatically recognized the clear image and withdrew it automatically (180 frame/s, Withdrawal speed: 36mm/s). The OCT data were analyzed by the ILUMIEN OPTIS Imaging System (Abbott Medical, Westfort,USA). OCT confirmed the long stenosis and showed lipid plaques with intact fibrous cap and linear cholesterol crystals (Figures 1B+C). Given the length of the target lesion and the patient's unwillingness to undergo stent implantation, treatment with a drug-coated balloon (DCB) was contemplated.

The percutaneous intervention of the right vertebral artery was performed under general anesthesia. After placement of an 8F catheter sheath in femoral artery, an 8F guide catheter was advanced to the subclavian artery over a 0.018-inch guidewire (Control Wire, Boston Scientific, COSTA RICA, USA). Then a 0.014-inch micro-guide-wire (Runthrough, TERUMO, Shizuoka perfecture, Japan). was passed through the vertebral artery stenosis into the V2 segment. A 3.5 x 30

Vol.14, No. 1, pp. 29-31, Published March, 2023.

All Rights Reserved by JVIN. Unauthorized reproduction of this article is prohibited.

*Corresponding Author: Dr. Adnan I. Qureshi, Department of Neurology, University of Missouri - Columbia, CS & E Building, 5 Hospital Drive, CE507, Columbia, MO 65212, E-mail: qureshai@gmail.com.

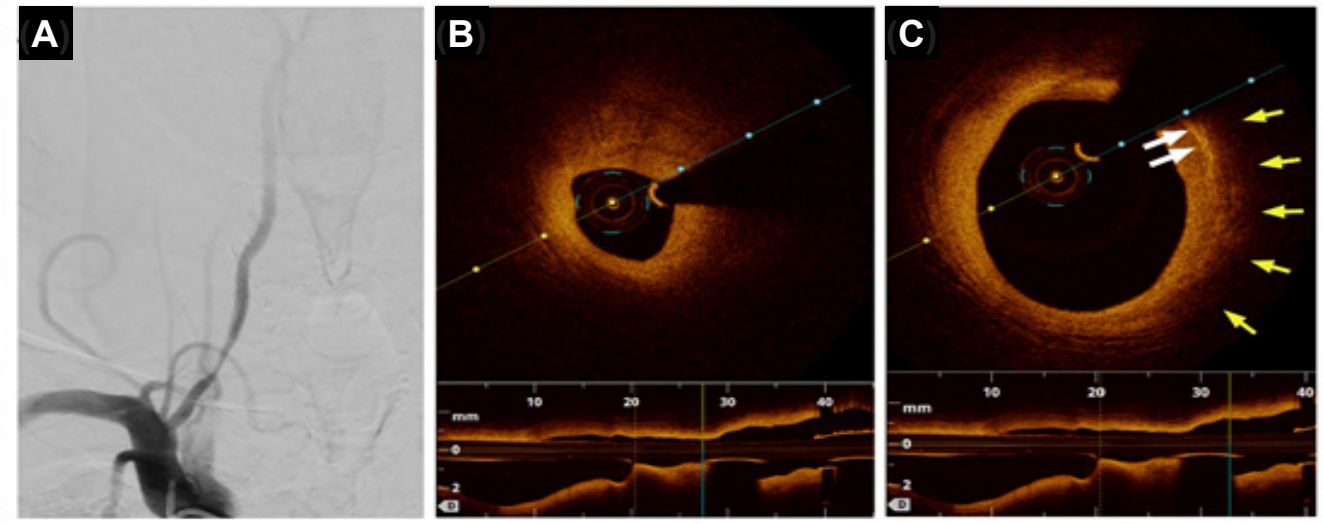

FIGURE 1: Target Anatomy and OCT Before Endovascular Intervention.
(A) Angiogram shows severe stenosis of the proximal right vertebral artery.
(B) OCT shows the long stenosis and lipid plaques with intact fibrous cap.
(C) OCT shows linear cholesterol crystals (the white arrow) and lipid pools(the yellow arrow).

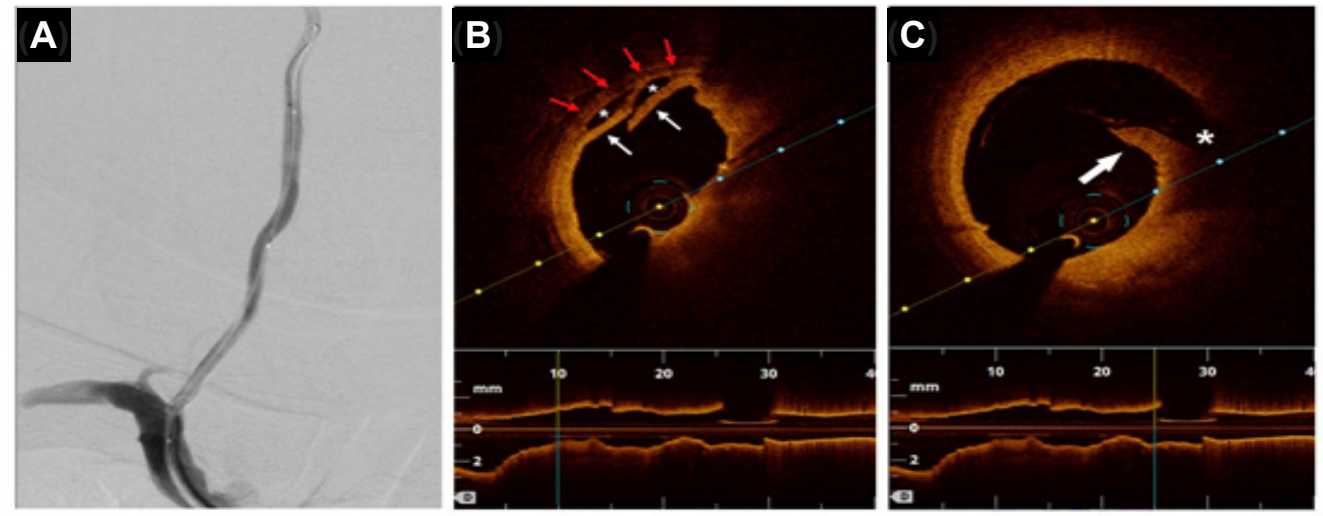

FIGURE 2: Target Anatomy and OCT after DCB Dilation.
(A) Angiogram shows good patency and no dissection after dilation of the stenosis with DCB
(B) OCT shows distinct flaps(the white arrow), false lumen(the asterisk) and tunica media(the red arrow).
(C) OCT shows distinct flap(the white arrow), exposed lipid pool(the asterisk).

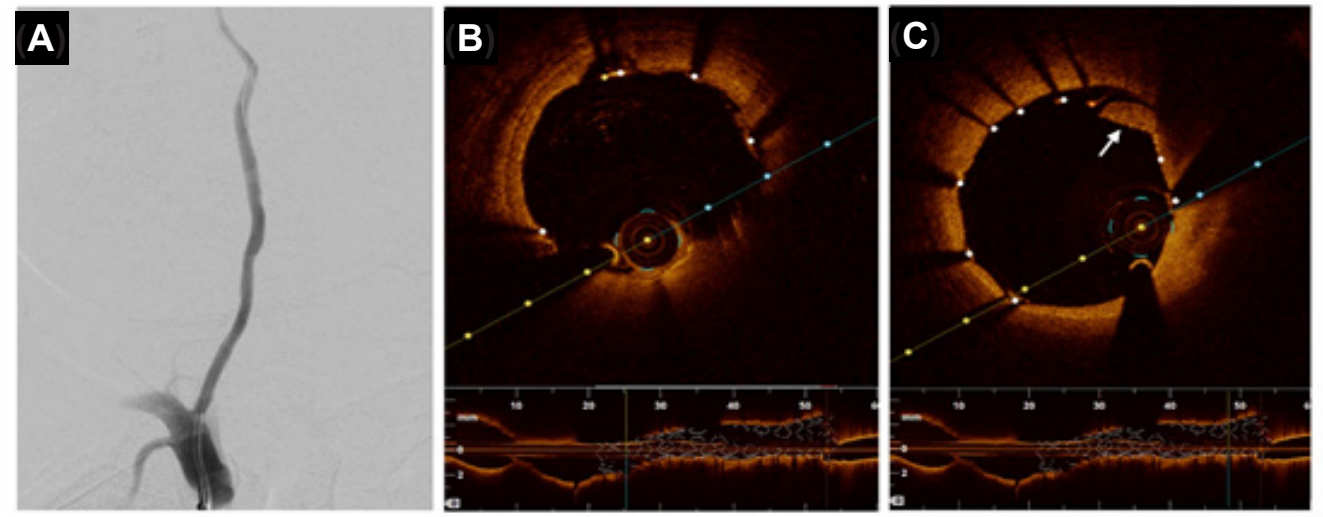

FIGURE 3: Target Anatomy and OCT after DES.
(A) Angiogram shows good patency of the right vertebral artery
(B+C) OCT shows the dissections are attached.

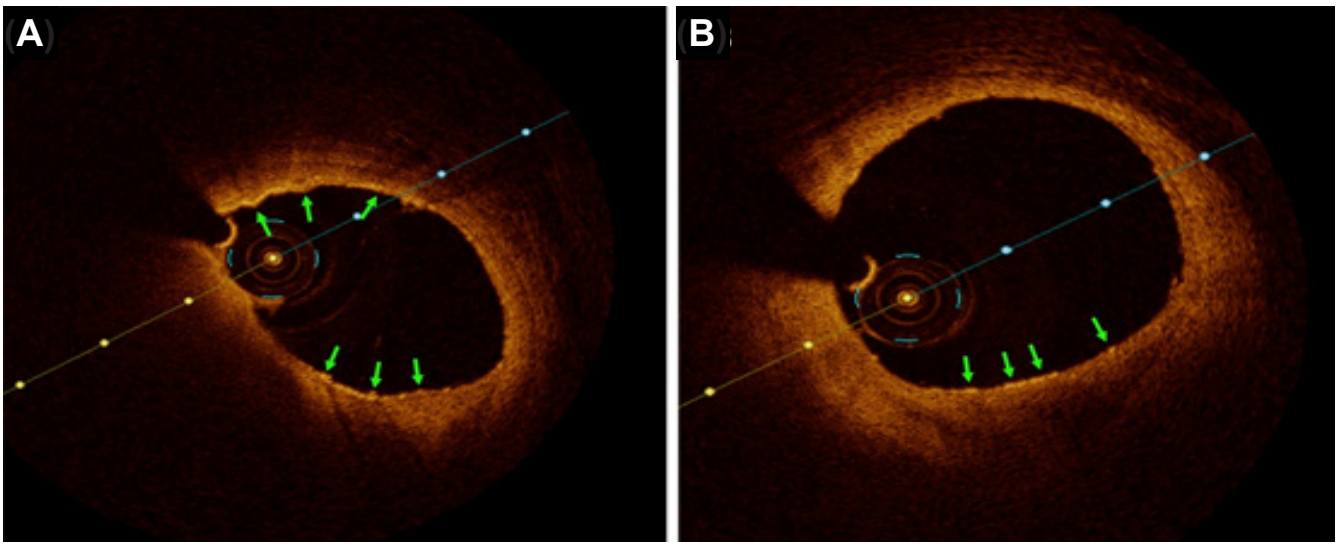

FIGURE 4: OCT after DCB Dilation.
(A+B)OCT shows high signals similar to cholesterol crystal on intimal surface; these signals are distributed unevenly(the green arrow).

mm Paclitaxel DCB was used to dilate the stenosis after predilation of the stenosis with a 4.0 x 30 mm balloon(Sterling, Boston Scientific, Two Scimed Place. USA). Inflation time was 60 s and inflation pressure was 8 atm. Angiogram showed good patency and no proximal dissection was found after dilation of the stenosis with DCB (Figures 2A). OCT showed two distinct dissections and exposed lipid pools (Figures 2B+C) possibly related to balloondilation. A 3.5 x 35 mm RQES drug eluting stent (DES) was selected as remedy in view of dissections and residual stenosis confirmed by OCT. The final angiogram showed good patency of the right vertebral artery and the dissections were sealed (Figures 3A+B+C). In addition, OCT showed new high signals similar to the appearance of cholesterol crystals on intimal surface after DCB dilation, which could be drug particles released from DCB. These signals are distributed unevenly on intial surface (Figures 4A+B).

A vascular ultrasound examination performed on the 6th postoperative day showed a return of blood flow velocity at the vertebral artery origin to normal (i.e., a decrease from 252 cm/s to 142 cm/s). The patient had no new neurological deficits after the procedure. Endovascular treatment of vertebral artery origin with DCB has been preliminarily proven to be feasible.[1,2] Nevertheless, angioplasty using DCB may lead to iatrogenic dissection, which is not reliably detected by angiography. OCT has the advantage of increasing the detection of the intimal flap.[3,4] Alfonso[5] found that no dissection was found by angiography in 74% of cases of spontaneous coronary dissection diagnosed by OCT. The first reported case suggests that OCT is feasible for imaging proxiaml vertebral artery lesion and may be more sentive to detect post angioplasty vertebral artery dissection.

REFERENCES

1. Gruber P, Berberat J, Kahles T, Anon J, Diepers M, Nedeltchev K, et al. Angioplasty using drug-coated balloons in ostial vertebral artery stenosis. Ann Vasc Surg. (2020) 64:157–62. doi: 10.1016/j.avsg.2019.10.043
2. Wang Y, Ma Y, Gao P, Chen Y, Yang B, Jiao L. First report of drug-coated balloon angioplasty for vertebral artery origin stenosis. JACC Cardiovasc Int. (2018) 11:500–2. doi: 10.1016/j.jcin.2017.09.040
3. Hoshi T,Sato A,Hiraya D,et al. Multimodality introcoronary imaging in spontaneous coronary artery dissection:inpacts of intravascular ultrasound,optical coherence tomography,and coronary angioscopy.Catheter Cardiovasc Interv,2013,81(3):E151-E154.
4. Nakagawa M,Shite J,Shinke T,et al. Ability of optical coherence tomography to visualize the entry port of spontanous coronary artery dissection.Circ J,2011,75(10):2505-2507.
5. Alfonso F,Paulo,M,Gonzalo N,et al.Diagonosis of spontaneous coronary artery dissection by optical coherence tomography.J Am Coll Cardiol,2012,59(12):1073-1079.