JVIN | Journal of Vascular and Interventional Neurology

OFFICIAL JOURNAL OF ZEENAT QURESHI STROKE INSTITUTE

Scepter Mini for the Treatment of an Anterior Ethmoidal Artery Dural Arteriovenous Fistula: Technical Case Report

Timothy G. White, MD[1], Kevin A. Shah, MD[1], Sharon C. Bossert, MD[1], Athos Patsalides, MD[1], Henry H. Woo, MD[1], Thomas Link, MD[1,*]

[1] Department of Neurosurgery, Donald and Barbara Zucker School of Medicine at Hofstra/Northwell, Manhasset, NY, USA

Abstract

Background— Dural arteriovenous fistulas of the anterior skull base pose a particular challenge for interventionalists; thus, these lesions have historically been addressed surgically. The Scepter Mini dual-lumen balloon microcatheter is the smallest dual-lumen liquid embolic compatible catheter on the market and has the potential to revolutionize the treatment of these lesions. We present the treatment and cure of an anterior cranial fossa dural arteriovenous fistula treated trans-arterially through the ophthalmic artery using the Scepter mini microcatheter.

Methods— A 77-year-old male was incidentally found to have an anterior cranial fossa dural arteriovenous fistula fed by bilateral anterior ethmoidal arteries. Primary drainage was via a subfrontal cortical vein draining into a sylvian vein and then into the right Vein of Labbe. The patient underwent transarterial embolization of the dural arteriovenous fistula via the right ophthalmic artery with Onyx 18 via the Scepter Mini dual-lumen balloon microcatheter.

Results— The fistula was angiographically cured, and the proximal ophthalmic artery and central retinal artery were preserved. The patient was intact after the procedure and at follow up.

Conclusion— Anterior cranial fossa dural arteriovenous fistulas were classically thought to be surgical lesions due to the challenging endovascular anatomy; however, the Scepter Mini allows for safe access of distal vasculature and immediate flow arrest for optimal safe delivery of liquid embolic agents. This case, along with others, suggest the remarkable value of this new dual-lumen balloon microcatheter.

Keywords— Dural arteriovenous fistula, liquid embolic agents, dual lumen balloon, endovascular embolization, balloon assisted embolization.

INTRODUCTION

Anterior cranial fossa dural arteriovenous fistulas account for only 10% of all dural arteriovenous fistulas and are classically fed by ethmoidal branches off of the ophthalmic arteries often with bilateral supply.[1,2] However, given the lack of a proximal dural sinus, their venous drainage is highly variable.[2] Due to the eloquent arterial supply coming from the ophthalmic artery combined with the often indirect or tortuous venous drainage, these dural arteriovenous fistulas have high interventional risk.[3] Instead, these lesions have classically been treated with surgical disconnection, as the fistulous point is generally easily accessible in the anterior cranial fossa.[3,4]

Conventional microcatheters for delivery of liquid embolic agents risk reflux, resulting in off-target embolization.[5] In the ophthalmic artery, this reflux may lead to blindness.[6] While this can be mitigated via the use of liquid embolic compatible dual-lumen balloon catheters, the balloon stiffens and thickens these catheters, preventing their use in small, distal vessels.[7] The Scepter Mini is a dual-lumen balloon microcatheter that has been previously used for the treatment of anterior cranial fossa dural arteriovenous fistulas.[5,8] Given the novel utility of this device, we describe the use of the Scepter Mini dual-lumen balloon for the treatment of an anterior cranial fossa dural arteriovenous fistula.

CLINICAL PRESENTATION

A 77-year-old male with a history of head and neck squamous cell carcinoma was incidentally found to have an anterior cranial fossa dural arteriovenous fistula on a screening scan after surgical tumor resection. The patient was neurologically intact, but initial computed tomography with contrast demonstrated a possible venous aneurysm. Given

Vol.14, No. 1, pp. 12-15, Published March, 2023.

All Rights Reserved by JVIN. Unauthorized reproduction of this article is prohibited.

*Corresponding Author: Dr Thomas Link, MD, Assistant Professor of Neurosurgery, Department of Neurosurgery, Northwell Institute of Neurology and Neurosurgery, Zucker School of Medicine at Hofstra/Northwell, 300 Community Drive, 9 Tower, Manhasset, NY 11030, E-mail: tlink@northwell.edu.

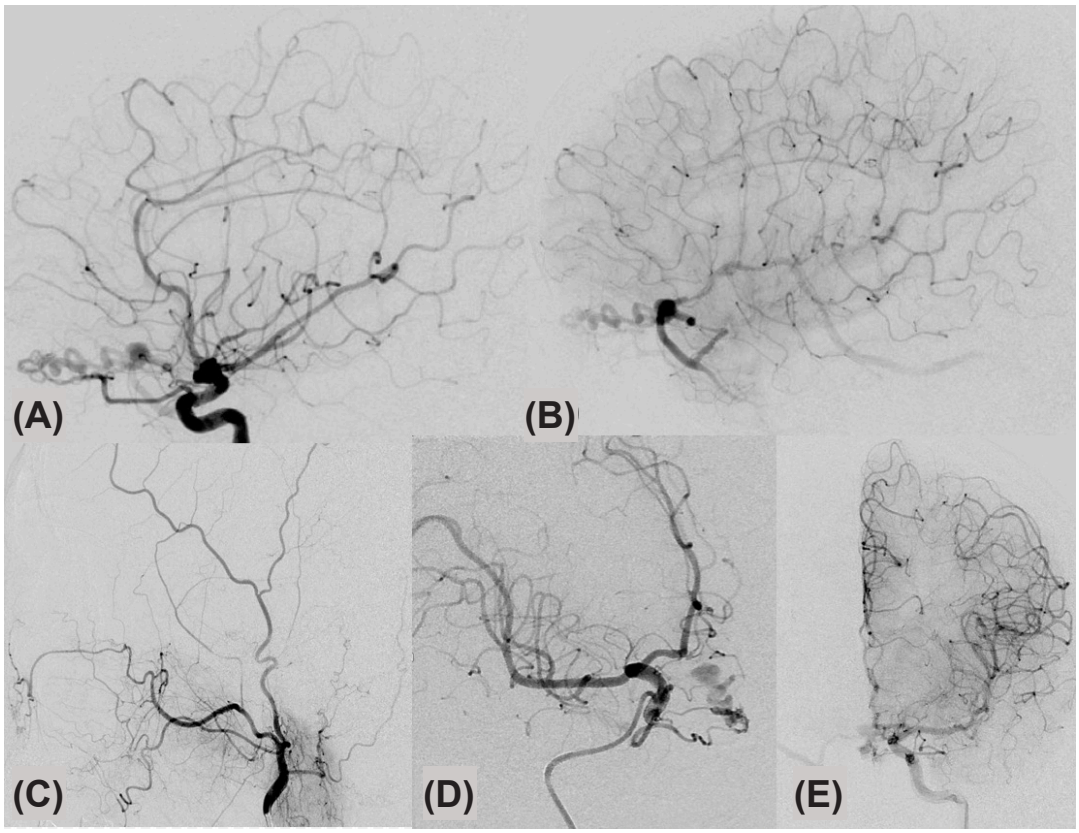

FIGURE 1: (A) Right ICA lateral injection. This demonstrated the ethmoidal fistula coming from the ophthalmic artery. (B) Late phase of the right ICA lateral injection. This demonstrated the fistula and the venous ectasia with venous drainage into the sylvian system and subsequently into the vein of Labbe. (C) Right external carotid artery injection. This demonstrated no fistula feeders. (D) Right ICA oblique anterior posterior injection. This demonstrated the anterior ethmoidal fistula. (E) Left ICA anterior posterior injection. This demonstrated some supply from the left anterior ethmoidal arteries to the fistula.

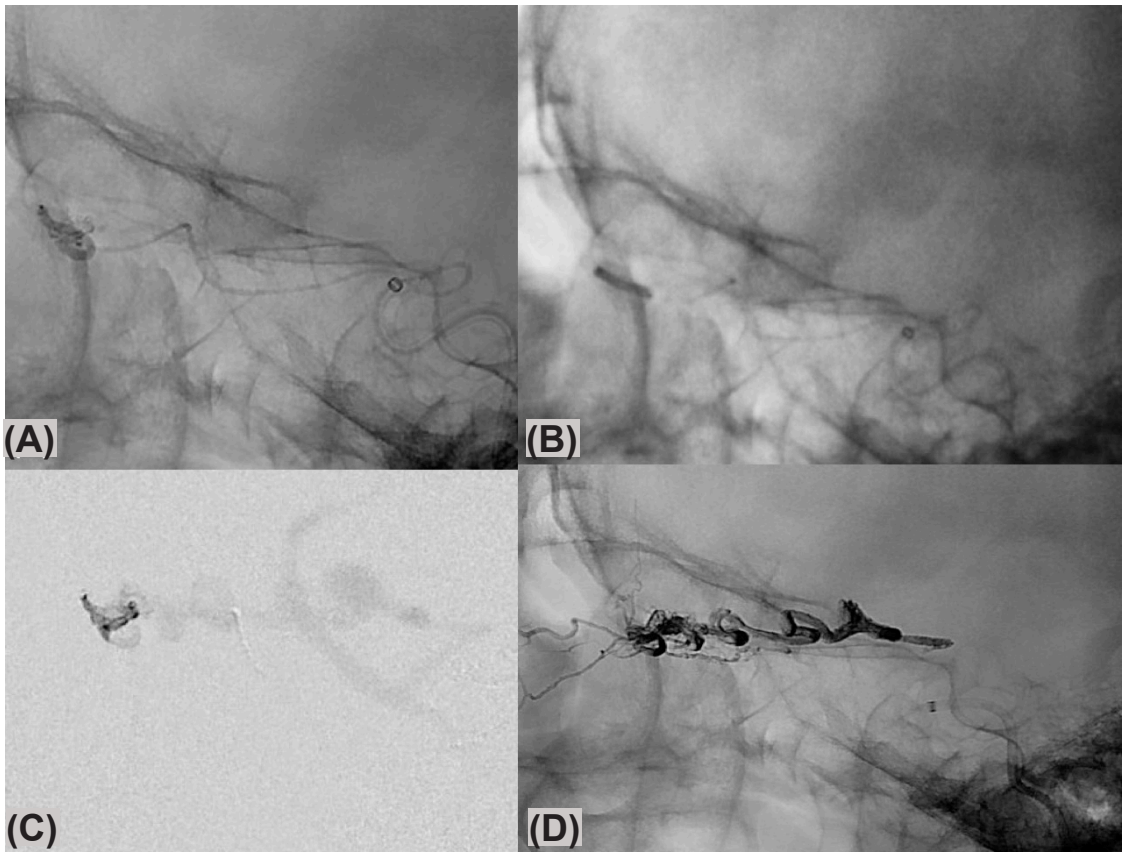

FIGURE 2: (A) Lateral unsubtracted view. This demonstrates the scepter mini distally placed in the ophthalmic artery, distal to the take-off of the central retinal artery prior to balloon inflation. (B) Lateral unsubtracted view. This demonstrates the scepter mini balloon now inflated in the distal ophthalmic artery. (C) Microcatheter injection. The microcatheter was then injected from the scepter mini balloon after inflation. (D) Onyx cast. The Onyx cast after a single injection of Onyx 18 demonstrated the penetration of the onyx into the fistula and vein, casting the venous ectasia and showing no evidence of reflux into the ophthalmic artery.

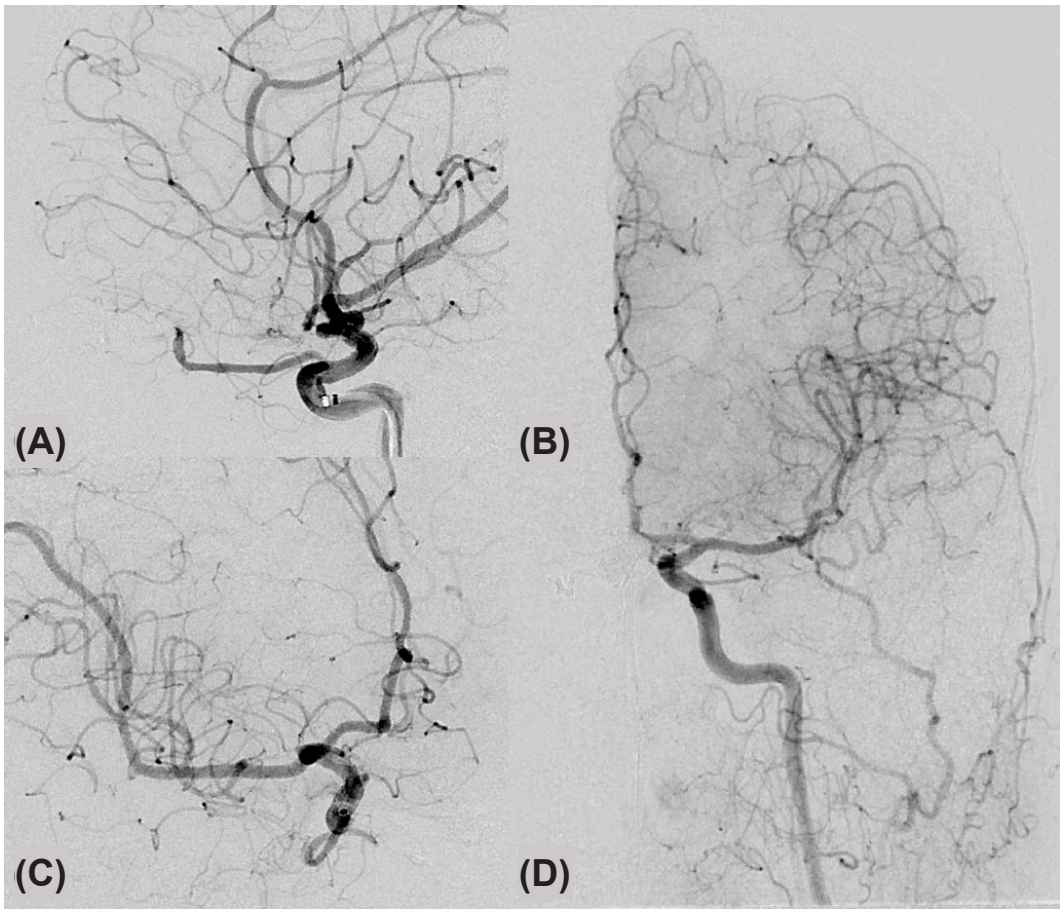

FIGURE 3: (A) Lateral view of post-onyx right ICA injection. This demonstrated no residual fistula and a patent ophthalmic artery. (B) Oblique anterior posterior view of post-onyx right ICA injection. This demonstrated no residual fistula. (C) Left carotid injection. This demonstrated no filling of the fistula from the contralateral carotid after injection of onyx.

these findings, the patient underwent diagnostic cerebral angiography.

Angiography revealed a Cognard type IV anterior cranial fossa dural arteriovenous fistula with arterial flow from bilateral ethmoidal branches (Figure 1, 1A and 1D). Primary drainage was from a right frontal cortical vein with associated venous ectasia into the right sided sylvian veins and ultimately into the Vein of Labbe (Figure 1, 1B). There was no contribution from the external carotid artery circulation and no choroidal blush seen with injection of the right external carotid (Figure 1, 1C). The right ophthalmic artery gave off the central retinal artery based on the presence of the choroidal blush on the right internal carotid artery injection (Figure 1, 1A and 1D). Upon injection of the left internal carotid artery, the fistula was found to be filling via left sided ethmoidal branches off the left ophthalmic artery (Figure 1, 1E). The patient elected to undergo attempted endovascular treatment prior to any surgical intervention, and he consented to the procedure.

A 5F Fubuki sheath (Asahi) was advanced into the proximal cervical segment of the right internal carotid artery. The patient was heparinized to an activated clotting time twice above baseline. Three milligrams of verapamil were administered into the right internal carotid artery to prevent iatrogenic vasospasm. A 5F Sofia EX (MicroVention, Aliso Viejo, CA) was subsequently navigated over a guidewire into the cavernous portion of the internal carotid artery. A Synchro 2 microwire was then advanced into the right ophthalmic artery for extra support. The Scepter Mini balloon (MicroVention, Aliso Viejo, CA) was then advanced over a 0.008" Hybrid double angle microwire into the right ophthalmic artery as distally as possible, well past the central retinal artery takeoff. The balloon was inflated within an arterial diameter of 1.2mm.

Superselective angiography of the right ophthalmic artery was performed before and after balloon inflation (Figure 2, 2A-C). There was no choroidal blush demonstrated on the superselective angiography. Once the balloon was inflated, dimethyl sulfoxide followed by Onyx 18 was injected (Figure 2, 2D). The injection was stopped after Onyx penetrated past the presumed fistulous point. The Scepter mini was then deflated and removed. Follow up angiography from the Sofia intermediate catheter showed no evidence of residual arteriovenous fistula. The right ophthalmic artery was patent, and there was good choroidal blush, although there was slow flow through the right ophthalmic artery (Figure 3, 3A-B). Follow up angiography from the left internal carotid artery showed no residual shunting (Figure 3, 3C).

The patient was neurologically intact after the procedure and was discharged post-procedure day 1. Given the stagnation seen on the right ophthalmic artery post-procedure, the patient was discharged on apixiban for one week. At follow up, the patient was off apixaban and neurologically intact without visual complaints.

DISCUSSION

Anterior cranial fossa fistulas are most often fed by ethmoidal branches off the ophthalmic artery and drain directly into cortical veins, resulting in high risk of rupture.[9,10] Therefore, treatment is often recommended. Anterior cranial fossa dural arteriovenous fistulas have long been considered surgical lesions, for current literature describes relatively poor cure rates using endovascular modalities.[11] The is mainly due to the challenge of injecting liquid embolic agents into the small ophthalmic artery, which is difficult to navigate and has no tolerance for reflux due to risk of blindness.[2,6] To address this, prior studies have shown that dual-lumen balloon catheters can act as a proximal plug therefore preventing reflux, thus avoiding off-target embolization.[7] However, older generation balloons were stiff with a significantly larger caliber than other liquid embolic microcatheters, limiting their use in distal lesions with small arterial feeders.[5]

Therefore, significant advancements are needed prior to adopting endovascular embolization as a first line therapy for these lesions. This report describes the utility of the new Scepter Mini dual-lumen balloon microcatheter for the delivery of liquid embolic agent for the treatment of an anterior cranial fossa dural arteriovenous fistula. As demonstrated here and several other series, the Scepter mini can fit into small, tortuous vessels, distal to the central retinal artery and subsequently prevent reflux, therefore optimizing the delivery of liquid embolic to the fistulous point.[5,8,12]

Recently, transvenous approaches to shunting lesions have come into favor with early evidence suggesting high rates of cure.[13,14] In one of the largest series of anterior cranial fossa dural arteriovenous fistulas, the authors reported that transvenous approaches were more successful than transarterial approaches for the obliteration of these lesions.[15] Technological advancement has been the key to transvenous approaches, as better support catheters and better navigability of microcatheters now allow for navigation of distal sinuses into cortical veins.[7,14] Based on the current report, we believe the Scepter mini would also be an excellent catheter choice for distal venous access of shunting lesions.

CONCLUSION

Ultimately, this case, as well as other series of the Scepter Mini in the literature demonstrate the technical value of this small dual-lumen balloon. It will certainly be a valuable tool in the interventionalists armamentarium and facilitate the treatment of complex neurovascular lesions.

DECLARATIONS

Conflicts of Interest

None.

Acknowledgments

None.

Financial Disclosures

None

REFERENCES

1. Xu K, Ji T, Li C, Yu J. Current status of endovascular treatment for dural arteriovenous fistulae in the anterior cranial fossa: A systematic literature review. Int J Med Sci. 2019;16(2):203-211.
2. Agid R, Terbrugge K, Rodesch G, et al. Management strategies for anterior cranial fossa (ethmoidal) dural arteriovenous fistulas with an emphasis on endovascular treatment. J Neurosurg. 2009;110(1):79-84.
3. Choi HJ, Cho CW. Anterior cranial fossa dural arteriovenous fistulae presenting as subdural hematoma. J Korean Neurosurg Soc. 2010;47(2):155-157.
4. Gross BA, Du R. Surgical treatment of high grade dural arteriovenous fistulae. J Clin Neurosci. 2013;20(11):1527-1532.
5. Pulli B, Sussman ES, Mayercik V, et al. Initial experience with the Scepter Mini dual-lumen balloon for transophthalmic artery embolization of anterior cranial fossa dural arteriovenous fistulae. J Neurointerv Surg. 2020;12(11):1132-1136.
6. Li Q, Fang YB, Huang QH, et al. Transarterial embolization of dural arteriovenous fistulas of the anterior cranial fossa with Onyx. J Clin Neurosci. 2013;20(2):287-291.
7. Spiotta AM, Hawk H, Kellogg RT, et al. Transfemoral venous approach for Onyx embolization of anterior fossa dural arteriovenous fistulae. J Neurointerv Surg. 2014;6(3):195-199.
8. Vollherbst DF, Chapot R, Wallocha M, et al. First clinical multicenter experience with the new Scepter Mini microballoon catheter. J Neurointerv Surg. 2021;13(3):261-266.
9. Tanei T, Fukui K, Wakabayashi K, et al. Dural arteriovenous fistula in the anterior cranial fossa: four case reports. Neurol Med Chir (Tokyo). 2008;48(12):560-563.
10. Lv X, Li Y, Liu A, et al. Endovascular embolization of dural arteriovenous fistulas of the anterior cranial fossa: three case reports. Neurol Res. 2008;30(8):852-859.
11. Kakarla UK, Deshmukh VR, Zabramski JM, et al, McDougall CG, Spetzler RF. Surgical treatment of high-risk intracranial dural arteriovenous fistulae: clinical outcomes and avoidance of complications. Neurosurgery. 2007;61(3):447-457; discussion 457-449.
12. White TG, Shah KA, Turpin J, et al. Single institution early clinical experience with the Scepter Mini balloon catheter. Neuroradiol J. 2021:19714009211013495.
13. Defreyne L, Vanlangenhove P, Vandekerckhove T, et al. Transvenous embolization of a dural arteriovenous fistula of the anterior cranial fossa: preliminary results. AJNR Am J Neuroradiol. 2000;21(4):761-765.
14. Limbucci N, Leone G, Nappini S, et al. Transvenous Embolization of Ethmoidal Dural Arteriovenous Fistulas: Case Series and Review of the Literature. World Neurosurg. 2018;110:e786-e793.
15. Dabus G, Kan P, Diaz C, et al. Endovascular treatment of anterior cranial fossa dural arteriovenous fistula: a multicenter series. Neuroradiology. 2021;63(2):259-266.