JVIN | Journal of Vascular and Interventional Neurology

OFFICIAL JOURNAL OF ZEENAT QURESHI STROKE INSTITUTE

Bilateral Duplication of the Cervical Internal Carotid Artery

Nozomi Sasaki, MD[1,*], Yoshihito Hasegawa, MD[1], Motoshi Sawada, MD, PhD[1]

[1] Department of Neurosurgery, Matsunami General Hospital, , Dendai, Kasamatsu Cho, Hashima Gun, Gifu, Japan

Abstract

Duplicated cervical internal carotid artery (ICA) is a very rare variant. The frequency is unknown and there are few reports so far. We report a case of bilateral duplicated ICA pointed out incidentally. The ICA is embryologically divided into segments by primitive blood vessels, and partial regression or agenesis in these segment results in variant of ICA that use alternative blood vessels. The duplicated ICA is likely to occur distal portion of cervical ICA and reaches inside of the carotid canal. The carotid branch of the pharyngeal branch of the ascending pharyngeal artery runs around the ICA and anastomoses with the artery of foramen lacerum of ICA in the carotid canal. The duplicated ICA may be embryologically involved in the carotid branch of ascending pharyngeal artery.

INTRODUCTION

Duplicated cervical internal carotid artery (ICA) is a very rare variant compared with duplication of other intracranial arteries such as the basilar artery and the middle cerebral artery. The frequency is unknown. Duplicated cervical ICA looks like dissection or floating thrombi on a computed tomography angiography (CTA) or digital subtraction angiography (DSA), but its essence consists of two luminal structure with completely separate cavities. We report a case of bilateral duplicated ICA pointed out incidentally.

CASE PRESENTATION

A 54-year-old man with no medical history was aware of headache. Head computed tomography showed right subcortical hemorrhage in the temporal lobe and subarachnoid hemorrhage in the right sylvian fissure. There was no cerebral aneurysm on CTA and DSA. Insteadly, the distal portion of right cervical ICA was visualized in a slit shape and duplicated (Figure 1A, C and D). The duplication was localized with a length of about 25 mm continuous from the distal cervical portion to the entrance of carotid canal. Although not as clear as on the right side, the source image of CTA showed that the left ICA also duplicated at the same elevation (Figure 1B). We diagnosed subarachnoid hemorrhage of unknown origin or penetration of subcortical hemorrhage of temporal lobe into subarachnoid space. In repeated CTA, the shape of bilateral duplicated cervical ICA did not change (Figure 2A and B). His clinical course was good, and he was discharged 3weeks after the onset.

DISCUSSION

According to previous reports, there is no consensus on the formation of duplicated ICA, but there are two main assumptions. First, the cause of duplication is secondary change after previous dissection associated with trauma and iatrogenic disorder. There are a few reports that these secondary post dissection change appear to be duplicated ICA.[1]

The second idea of duplicated ICA is the change associated with embryonic anomaly.[2] The ICA occur from third branchial arch artery and the distal segment of the paired dorsal aortae during the 3mm embryonic stage. The ICA is embryologically divided into segments by primitive blood vessels, and partial regression or agenesis in these segment results in variant of ICA that use alternative blood vessels.[2] This typical variant is aberrant ICA that use the anastomosis developed between inferior tympanic branch of the ascending pharyngeal artery and caroticotympanic branch of the ICA.

In our case, there was no history of trauma or cerebral angiography, and both ICAs have duplicated change at similar position. Thus, we consider that embryonic anomaly is more appropriate than secondary change after dissection.

Although embryological theory of aberrant ICA has been established, the formation of duplicated ICA is not clearly known, and only a few speculations are made. It is considered that the persistence of the ductus caroticus or the regression of the segment ICA and the use of branch of the ascending pharyngeal artery like aberrant ICA.[2-4] The ductus caroticus is vascular structure that connects the third and fourth aortic

Vol.14, No. 1, pp. 26-28, Published March, 2023.

All Rights Reserved by JVIN. Unauthorized reproduction of this article is prohibited.

*Corresponding Author: Nozomi Sasaki, Email address:nshope0130@yahoo.co.jp

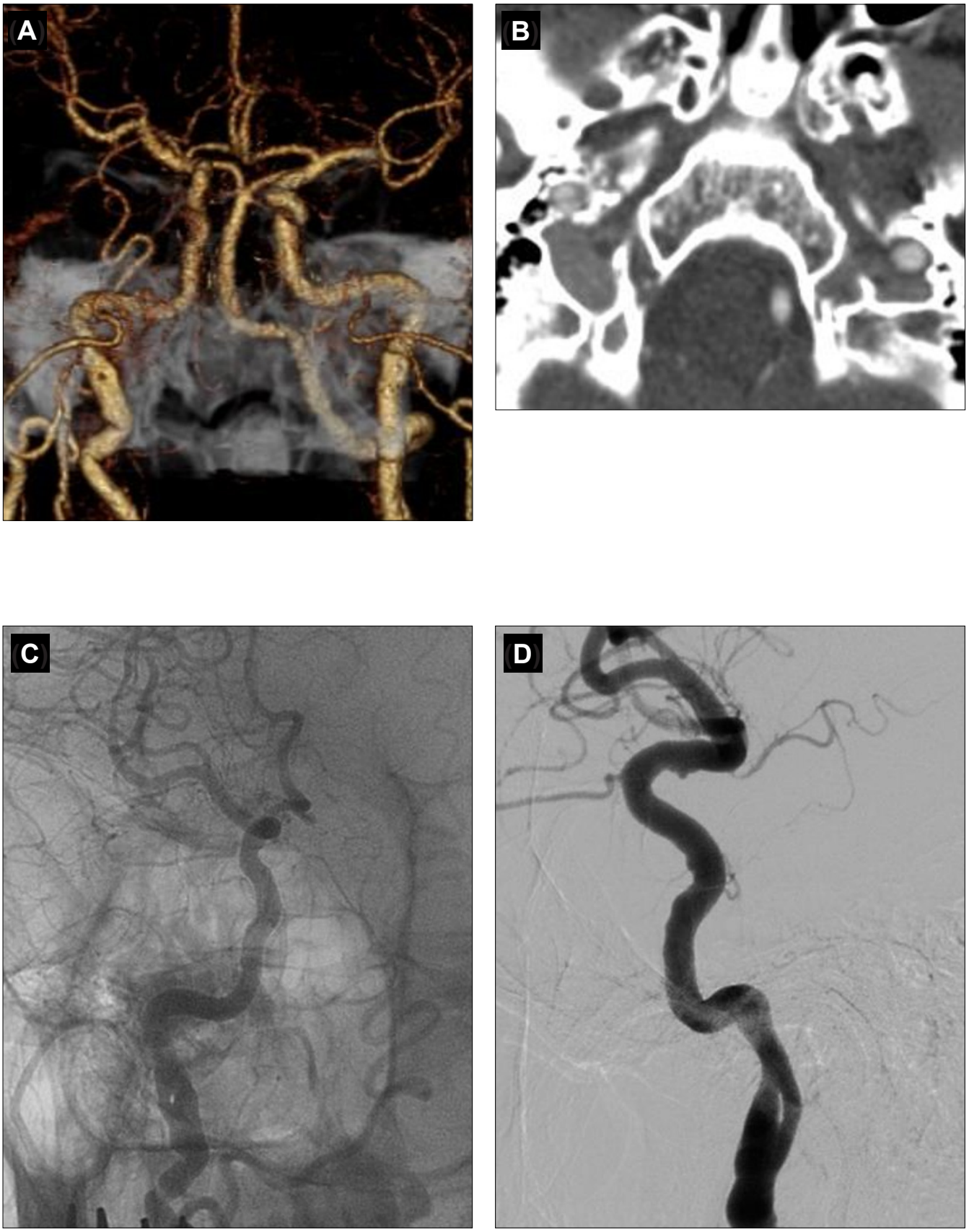

FIGURE 1: A: 3D reconstructed CTA shows a slit shape and duplication in the distal portion of right cervical ICA (arrow). The left ICA is also dilatated at the same elevation. B: Axial CTA shows two lumen separated by a slit-like defect in the right as well as the left ICA (arrows). C and D: Oblique (arrow in C) and lateral view (arrow in D) of DSA of the right ICA show the duplication at cervical portion.

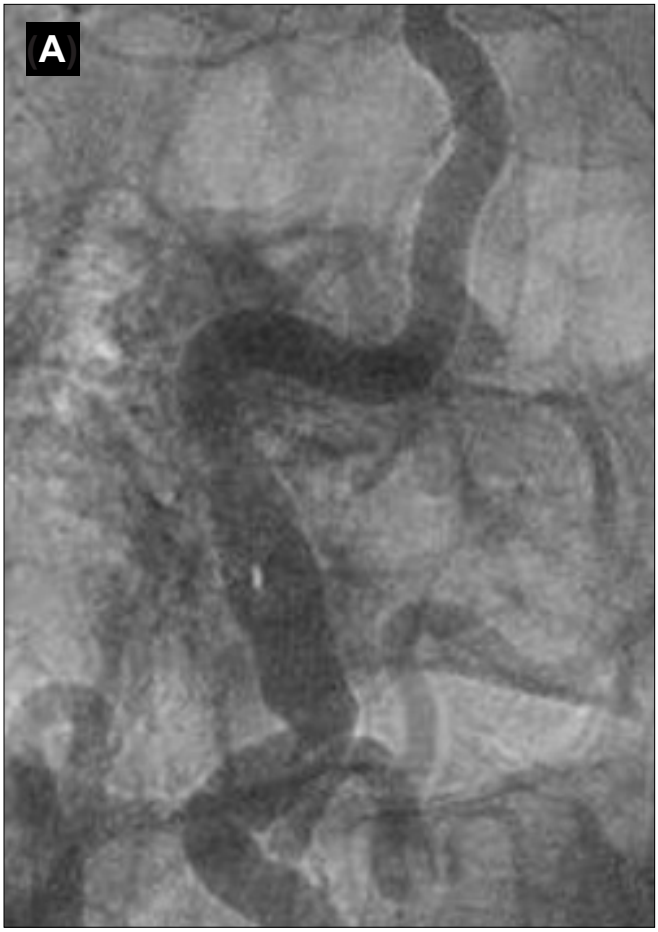



FIGURE 2: A and B: Oblique (arrow in A) and lateral view (arrow in B) of DSA of the right ICA at 1 week after onset show no change in shape of duplicated ICA.

arches, and it normally regresses until 12mm crown-rump length.[3] On the other hand, if the cause of duplicated ICA is the regression of the segment ICA and the use of alternative blood vessel such as aberrant ICA, it can be considered logically. Lucian et al reviewed 13 cases of duplicated ICA and suggested that 11 cases were localized from the distal portion of cervical ICA to the carotid canal.[3] This fact supports the possibility that the duplicated ICA is likely to occur distal portion of cervical ICA. Aberrant ICA is also a variant of same portion. However, unlike aberrant ICA, the duplicated ICA does not include lateral extension of ICA. In addition, the slit-like duplication partially reaches inside of the carotid canal as in our case. Judging from these findings, it makes sense that the duplicated ICA may use the carotid branch of the pharyngeal branch of the ascending pharyngeal artery as collateral flow. John et al reported a case of bilateral aberrant ICA with bilateral duplicated ICA, using the carotid branch of the ascending pharyngeal artery as an additional collateral flow due to the stenosis at the inferior tympanic canal.[4] The carotid branch runs around the ICA after branching from the ascending pharyngeal artery, and anastomoses with the artery of foramen lacerum of ICA in the carotid canal.[2] We think that a localized ICA duplication with a slit was embryologically born by means of incomplete regression of the segment of the distal cervical ICA and utilization the carotid branch of the ascending pharyngeal artery surrounded ICA.

CONCLUSION

Duplicated ICA is a very rare variant, but knowing its presence may avoid unnecessary medical treatment. We considered that the duplicated ICA may be embryologically involved in the carotid branch of ascending pharyngeal artery.

Acknowledgments

None.

Disclosures

None

REFERENCES

1. Philippe Gailloud, Jeffrey Carpenter, Donald V Heck, and Kieran J Murphy. Pseudofenestration of the Cervical Internal Carotid Artery: A Pathologic Process that Simulates an Anatomic Variant. Am J Neuroradiol. 2004;25:421-424
2. S M Ching, H Alvarez, K Marsot-Dupuch, P Mercier, P Lasjaunias. "Duplicated" or "Multiple" Cervical Internal Carotid and Vertebral Arteries from Fenestration, Duplication and Vasa Vasorum to Segmental Rete. Interventional Neuroradiology. 2004;10:301-307
3. Lucian Marginean, Rares Cristian Filep, Cristian Constantin, Adrian Florian Balasa, Gheorghe Muhlfay. Fenestration of the cervical internal carotid artery misdiagnosed as dissection. Rom J Morphol Embryol. 2020;61(1):257-260
4. John D Roll, Martin A Urban, Theodore C Larson III, Philippe Gailloud, Pradeep Jacob, and H Ric Harnsberger. Bilateral Aberrant Internal Carotid Arteries with Bilateral Persistent Stapedial Arteries and Bilateral Duplicated Internal Carotid Arteries. Am J Neuroradiol. 2003;24:762-765